



NCCN Clinical Practice Guidelines in Oncology (NCCN Guidelines®)

Testicular Cancer

Version 2.2015

NCCN.org

Continue



* Robert J. Motzer, MD/Chair † P
Memorial Sloan Kettering Cancer Center

* Eric Jonasch, MD/Vice-chair †
The University of Texas
MD Anderson Cancer Center

Neeraj Agarwal, MD ‡
Huntsman Cancer Institute
at the University of Utah

Clair Beard, MD §
Dana-Farber/Brigham and Women's
Cancer Center

Sam Bhayani, MD ω
Siteman Cancer Center at Barnes-
Jewish Hospital and Washington
University School of Medicine

Graeme B. Bolger, MD †
University of Alabama at Birmingham
Comprehensive Cancer Center

Sam S. Chang, MD ω
Vanderbilt-Ingram Cancer Center

* Toni K. Choueiri, MD † P
Dana-Farber/Brigham and Women's
Cancer Center

* Brian A. Costello, MD, MS †
Mayo Clinic Cancer Center

Ithaar H. Derweesh, MD ω
UC San Diego Moores Cancer Center

Shilpa Gupta, MD †
Moffitt Cancer Center

Steven L. Hancock, MD § P
Stanford Cancer Institute

Jenny J. Kim, MD †
The Sidney Kimmel Comprehensive
Cancer Center at Johns Hopkins

Timothy M. Kuzel, MD ‡
Robert H. Lurie Comprehensive Cancer
Center of Northwestern University

Elaine T. Lam, MD †
University of Colorado Cancer Center

Clayton Lau, MD ω
City of Hope Comprehensive Cancer Center

Ellis G. Levine, MD †
Roswell Park Cancer Institute

Daniel W. Lin, MD ω
Fred Hutchinson Cancer Research Center/
Seattle Cancer Care Alliance

* M. Dror Michaelson, MD, PhD †
Massachusetts General Hospital Cancer Center

Thomas Olencki, DO †
The Ohio State University Comprehensive
Cancer Center - James Cancer Hospital
and Solove Research Institute

Roberto Pili, MD †
Roswell Park Cancer Institute

Elizabeth R. Plimack, MD, MS †
Fox Chase Cancer Center

Edward N. Rampersaud, MD ω
Duke Cancer Institute

Bruce G. Redman, DO †
University of Michigan
Comprehensive Cancer Center

Charles J. Ryan, MD † ω
UCSF Helen Diller Family
Comprehensive Cancer Center

Joel Sheinfeld, MD ω
Memorial Sloan Kettering Cancer Center

Brian Shuch, MD ω
Yale Cancer Center/Smilow Cancer Hospital

Kanishka Sircar, MD ≠
The University of Texas
MD Anderson Cancer Center

Brad Somer, MD †
St. Jude Children's Research Hospital/
University of Tennessee Health Science
Center

Richard B. Wilder, MD §
Moffitt Cancer Center

NCCN
Mary Dwyer, MS
Rashmi Kumar, PhD
Sarika Trikha, PharmD

† Medical oncology
‡ Hematology/Hematology oncology
§ Radiotherapy/Radiation oncology
P Internal medicine
ω Urology
≠ Pathology
* Writing Committee Member

Continue



[NCCN Testicular Cancer Panel Members](#)
[Summary of the Guidelines Updates](#)

[Workup, Primary Treatment, and Pathologic Diagnosis \(TEST-1\)](#)
[Pure Seminoma: Postdiagnostic Workup and Clinical Stage \(TEST-2\)](#)

- [Stage IA, IB \(TEST-3\)](#)
- [Stage IS \(TEST-3\)](#)
- [Stage IIA, IIB \(TEST-4\)](#)
- [Stage IIC, III \(TEST-4\)](#)

[Nonseminoma: Postdiagnostic Workup and Clinical Stage \(TEST-6\)](#)

- [Stage IA, IB, IS \(TEST-7\)](#)
- [Stage IIA, IIB \(TEST-8\)](#)
- [Postchemotherapy Management \(TEST-9\)](#)
- [Postsurgical Management \(TEST-10\)](#)
- [Stage IS, IIA S1, IIB S1, IIC, IIIA, IIIB, IIIC, and Brain Metastases \(TEST-11\)](#)

[Recurrence and Second-Line Therapy \(TEST-12\)](#)

[Follow-up for Seminoma \(TEST-A\)](#)

[Follow-up for Nonseminoma \(TEST-B\)](#)

[Principles of Radiotherapy for Pure Testicular Seminoma \(TEST-C\)](#)

[Risk Classification for Advanced Disease \(TEST-D\)](#)

[Primary Chemotherapy Regimens for Germ Cell Tumors \(TEST-E\)](#)

[Second-Line Chemotherapy Regimens for Metastatic Germ Cell Tumors \(TEST-F\)](#)

[Subsequent Chemotherapy Regimens for Metastatic Germ Cell Tumors \(TEST-G\)](#)

[Principles of Surgery for Germ-Cell Tumors \(TEST-H\)](#)

Clinical Trials: NCCN believes that the best management for any cancer patient is in a clinical trial. Participation in clinical trials is especially encouraged.

To find clinical trials online at NCCN Member Institutions, [click here: nccn.org/clinical_trials/physician.html](#).

NCCN Categories of Evidence and Consensus: All recommendations are category 2A unless otherwise specified.

See [NCCN Categories of Evidence and Consensus](#).

[Staging \(ST-1\)](#)

The NCCN Guidelines® are a statement of evidence and consensus of the authors regarding their views of currently accepted approaches to treatment. Any clinician seeking to apply or consult the NCCN Guidelines is expected to use independent medical judgment in the context of individual clinical circumstances to determine any patient's care or treatment. The National Comprehensive Cancer Network® (NCCN®) makes no representations or warranties of any kind regarding their content, use or application and disclaims any responsibility for their application or use in any way. The NCCN Guidelines are copyrighted by National Comprehensive Cancer Network®. All rights reserved. The NCCN Guidelines and the illustrations herein may not be reproduced in any form without the express written permission of NCCN. ©2015.



Updates in Version 2.2015 of the NCCN Guidelines for Testicular Cancer from Version 1.2015 include:

[MS-1](#)

- The Discussion section was updated to reflect the changes in the algorithm.

Updates in Version 1.2015 of the NCCN Guidelines for Testicular Cancer from Version 1.2014 include:

New to the Guidelines

• Follow-up

- ▶ The follow-up recommendations for both pure seminoma ([TEST-A](#)) and nonseminomatous germ cell tumor (NSGCT) ([TEST-B](#)) were extensively revised. For seminoma, the recommendation was removed from the algorithms and placed in tables.

Seminoma

[TEST-3](#)

• Stage IA, IB

▶ Primary treatment

- ◇ For single-agent carboplatin, the category was changed from a 1 to a 2A.
- ◇ The dose for RT was added, “20 Gy,” and the category was changed from a 1 to a 2A.

- ▶ The follow-up recommendations were removed from page and directed to new “Follow-up for Seminoma” section.

[TEST-4](#)

• For Stage IIA

- ▶ Primary treatment, the RT recommendation was revised, “RT to include para-aortic and ipsilateral iliac lymph nodes to a dose of 30 to ~~36~~ 36 Gy (preferred).”

• For Stage IIB

- ▶ Primary treatment, the RT recommendation was revised, “RT *in select non-bulky cases* to include para-aortic and ipsilateral iliac lymph nodes to a dose of ~~30 to~~ 36 Gy.”

- The follow-up recommendations after RT were removed from the page and directed to new “Follow-up for Seminoma” section.

[TEST-5](#)

- Post chemotherapy follow-up recommendations were removed from the page and directed to new “Follow-up for Seminoma” section.

[Continued on next page](#)

Updates in Version 1.2015 of the NCCN Guidelines for Testicular Cancer from Version 1.2014 include:

Nonseminoma

- Follow-up for nonseminoma links to corresponding tables were added throughout the section.

TEST-9

- Stage IB was removed from the postchemotherapy management page.
- Stage IIA, IIB treated with primary chemotherapy
 - ▶ Postchemotherapy management for negative markers, no mass, or residual mass <1 cm on CT scan:
 - ◇ Surveillance was changed from a category 2B to a 2A.
 - ◇ Nerve-sparing bilateral RPLND was modified by adding, “in selected cases.”

TEST-11

- Post-chemotherapy management
 - ▶ For a complete response, negative markers,
 - ◇ If original stage was Stage IS, the surveillance recommendation was changed from category 2B to a 2A.
 - ◇ If original stage was Stage IIA, S1; Stage IIB, S1; Stage IIC; or Stage IIIA, “Surveillance” was changed from a category 2B to a 2A and “Bilateral RPLND ± nerve-sparing” was modified by adding, “in selected cases.”

TEST-12

- Second-line therapy
 - ▶ For unfavorable prognosis and late relapse, after second-line therapy, the decision points “complete response” and “incomplete response or persistent disease” with corresponding treatment options replaced “persistent disease or relapse.”

Testicular Cancer

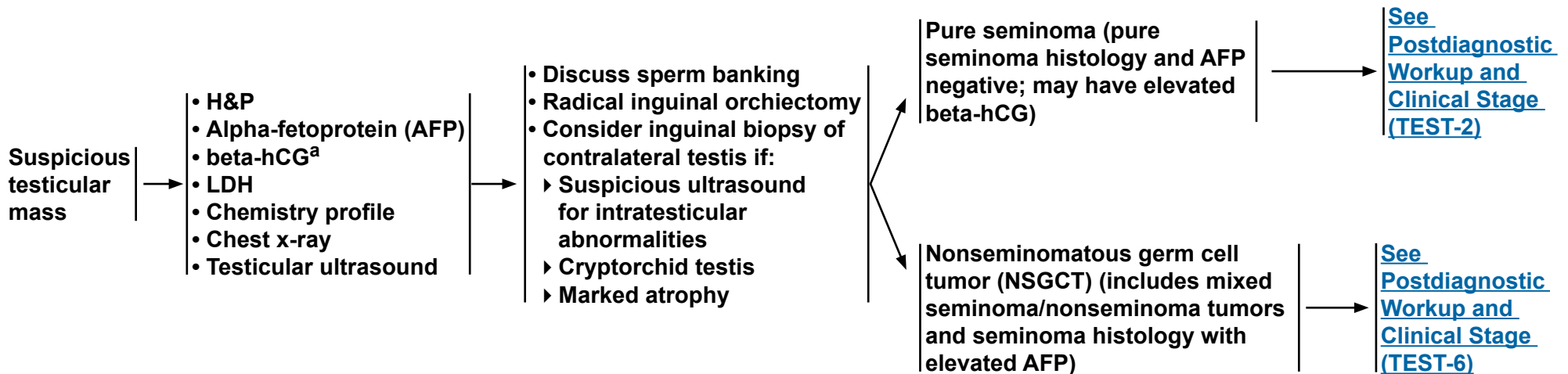
TEST-C 3 of 5

- For Stage IIA/B, the modified dog-leg field dose was revised, “Dose: The initial phase consists of treatment of modified dog-leg fields to 20.0 Gy (midplane) in 10 daily 2.0-Gy fractions ~~or 25.5 Gy in 15 daily 1.7-Gy fractions.~~”

WORKUP

PRIMARY TREATMENT^b

PATHOLOGIC DIAGNOSIS



^aQuantitative analysis of beta subunit.

^bThough rare, when a patient presents with rapidly increasing beta-hCG and symptoms related to disseminated disease and a testicular mass, chemotherapy can be initiated immediately without waiting for a biopsy diagnosis.

Note: All recommendations are category 2A unless otherwise indicated.
Clinical Trials: NCCN believes that the best management of any cancer patient is in a clinical trial. Participation in clinical trials is especially encouraged.

**PATHOLOGIC
DIAGNOSIS**

**POSTDIAGNOSTIC
WORKUP**

**CLINICAL
STAGE^e**

Pure seminoma^c
(pure seminoma histology
and AFP negative;^d may
have elevated beta-hCG)

- Abdominal/pelvic CT
- Chest CT if:
 - ▶ Positive abdominal CT or abnormal chest x-ray
- Repeat beta-hCG, LDH, AFP since TNM staging is based on post-orchiectomy values^e
- Brain MRI, if clinically indicated
- Bone scan, if clinically indicated
- Discuss sperm banking

Stage
IA, IB

Stage
IS

Stage
IIA, IIB

Stage
IIC, III

[See Primary Treatment
and Follow-up \(TEST-3\)](#)

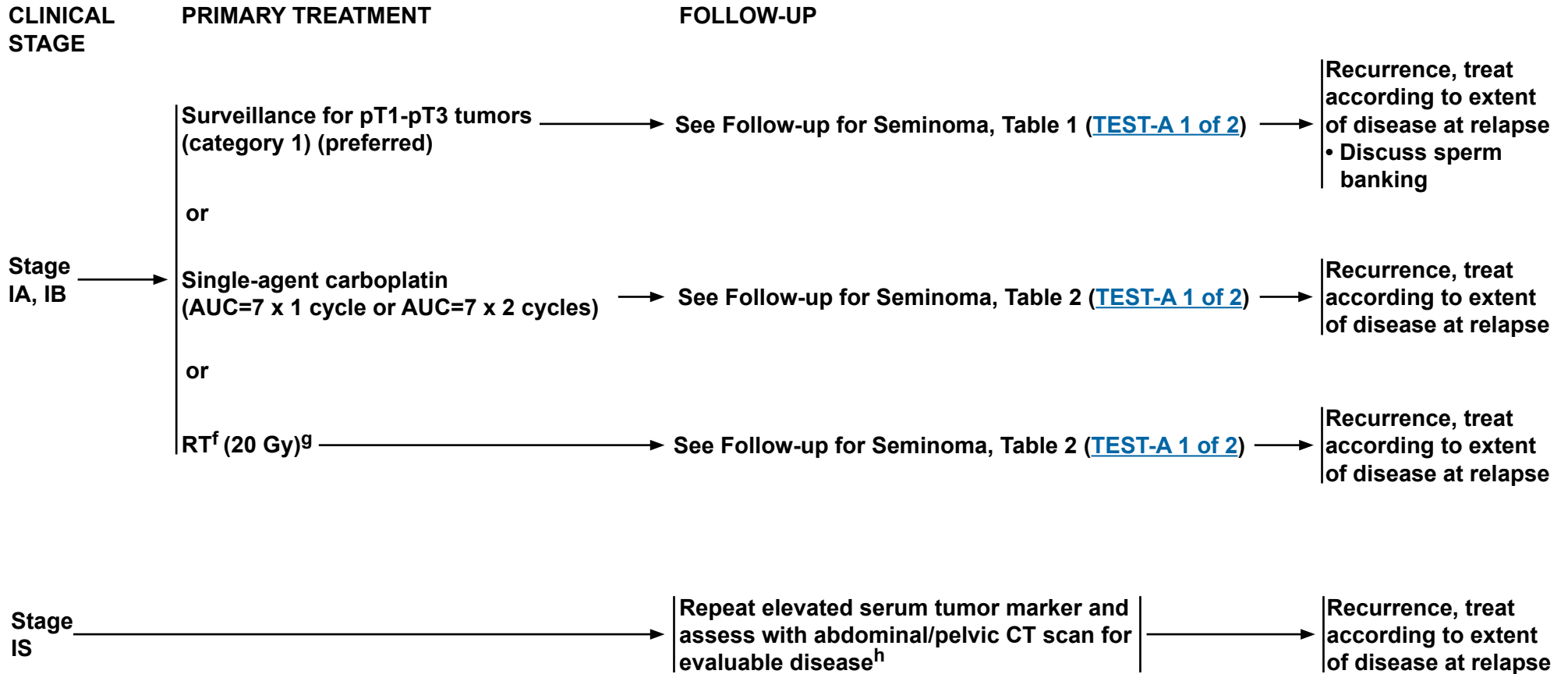
[See Primary Treatment
and Follow-up \(TEST-4\)](#)

^cMediastinal primary seminoma should be treated by risk status used for gonadal seminomas with etoposide/cisplatin for 4 cycles or bleomycin/etoposide/cisplatin for 3 cycles.

^dIf AFP positive, treat as nonseminoma.

^eElevated values should be followed after orchiectomy with repeated determination to allow precise staging.

Note: All recommendations are category 2A unless otherwise indicated.
Clinical Trials: NCCN believes that the best management of any cancer patient is in a clinical trial. Participation in clinical trials is especially encouraged.



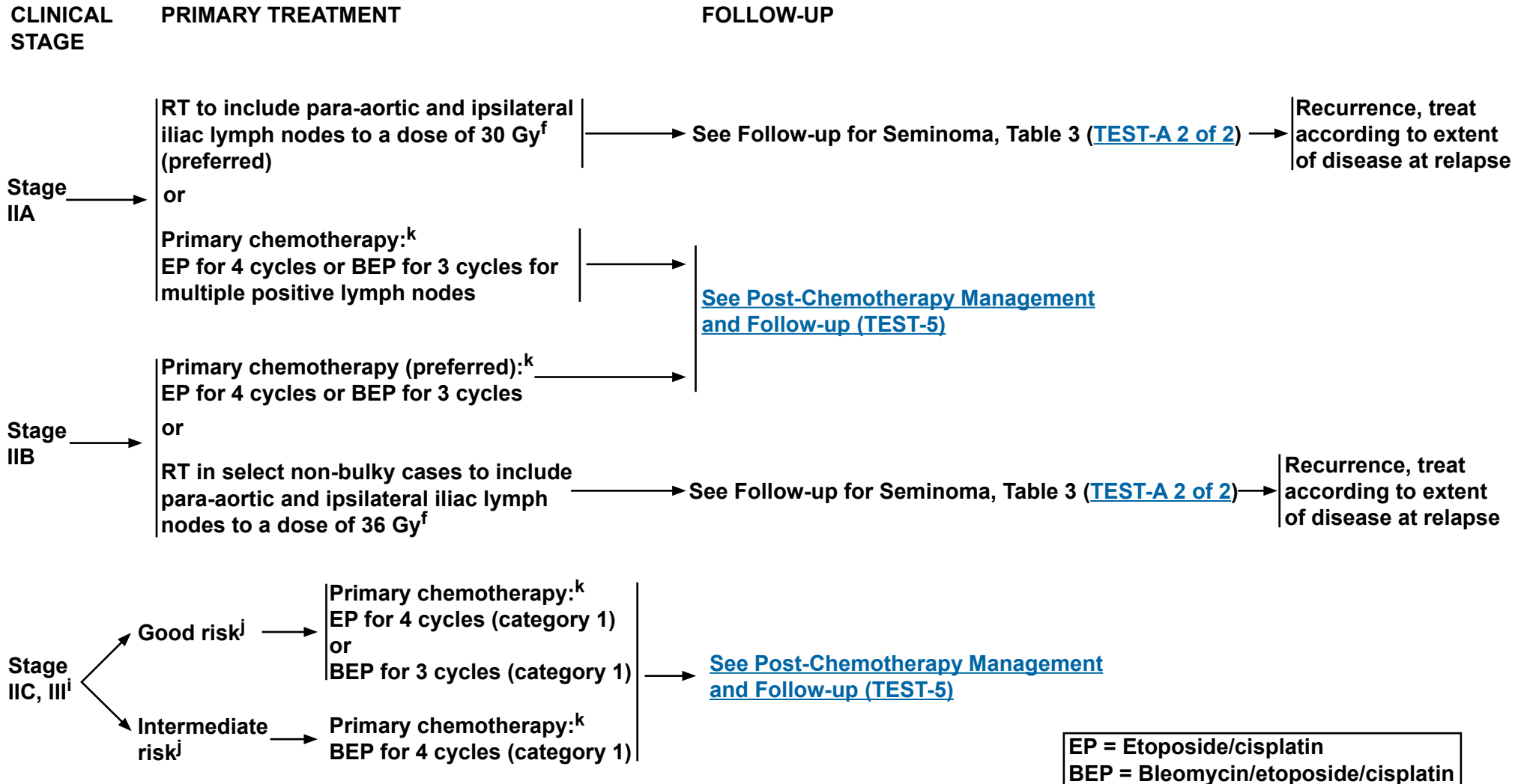
^fSee Principles of Radiotherapy for Pure Testicular Seminoma (TEST-C).

^gFor Stage I seminoma, long-term follow-up studies indicate an increase in late toxicities with radiation treatment. See Discussion.

^hFor further information on Stage IS, see Discussion.

Note: All recommendations are category 2A unless otherwise indicated.

Clinical Trials: NCCN believes that the best management of any cancer patient is in a clinical trial. Participation in clinical trials is especially encouraged.



^fSee Principles of Radiotherapy for Pure Testicular Seminoma (TEST-C).

ⁱAll stage IIC and stage III seminoma is considered good-risk disease except for stage III disease with non-pulmonary visceral metastases (eg, bone, liver, or brain), which is considered intermediate risk.

^jSee Risk Classification for Advanced Disease (TEST-D).

^kSee Primary Chemotherapy Regimens for Germ Cell Tumors (TEST-E).

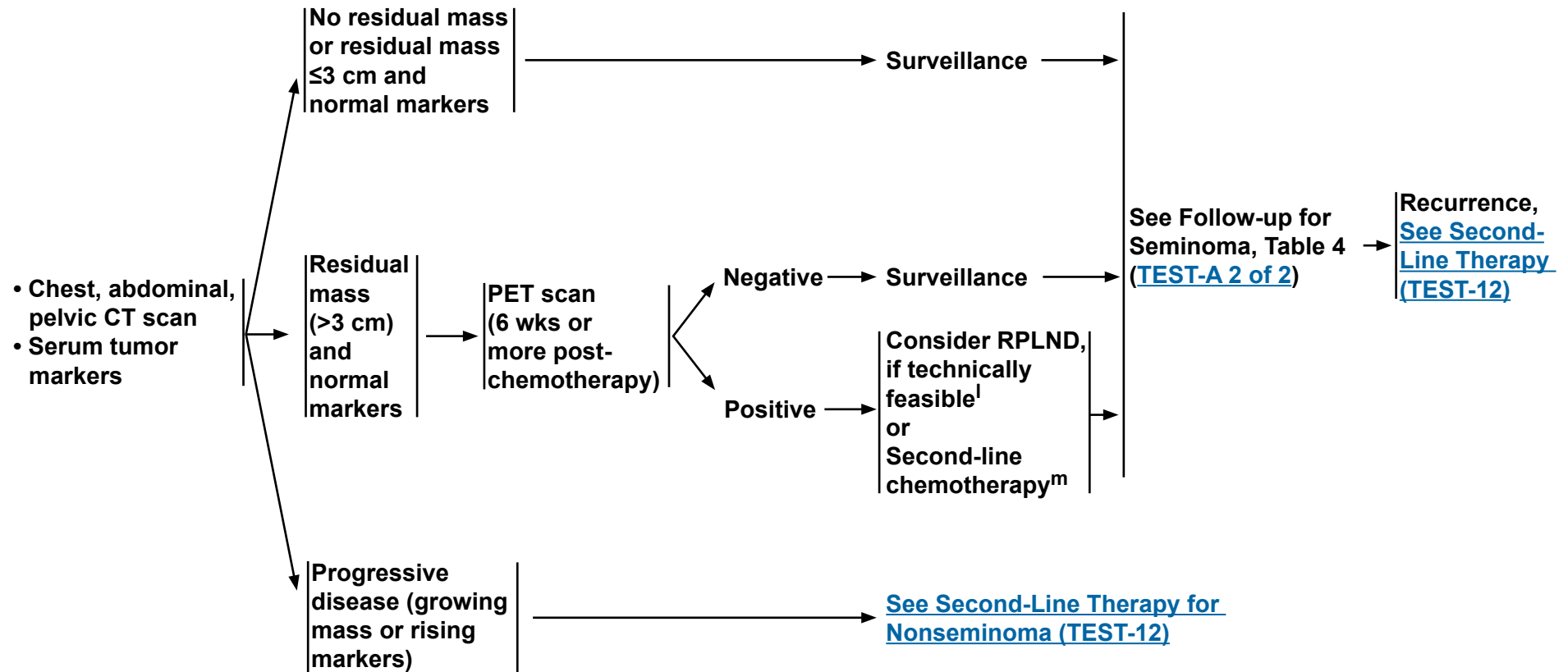
Note: All recommendations are category 2A unless otherwise indicated.

Clinical Trials: NCCN believes that the best management of any cancer patient is in a clinical trial. Participation in clinical trials is especially encouraged.

STAGE IIA, IIB, IIC, III AFTER PRIMARY TREATMENT WITH CHEMOTHERAPY

POST-CHEMOTHERAPY MANAGEMENT

FOLLOW-UP



¹If viable seminoma found by retroperitoneal lymph node dissection (RPLND), [see TEST-11](#) (residual embryonal, yolk sac, choriocarcinoma, or seminoma elements).
^m[See Second-Line Chemotherapy Regimens for Metastatic Germ Cell Tumors \(TEST-F\)](#).

Note: All recommendations are category 2A unless otherwise indicated.
Clinical Trials: NCCN believes that the best management of any cancer patient is in a clinical trial. Participation in clinical trials is especially encouraged.

PATHOLOGIC DIAGNOSIS

NSGCT (includes mixed seminoma/nonseminoma tumors and seminoma histology with elevated AFP)

POSTDIAGNOSTIC WORKUPⁿ

- Abdominal/pelvic CT ± chest imaging
- Repeat beta-hCG, LDH, AFP since TNM staging is based on post-orchietomy values^e
- Brain MRI, if clinically indicated
- Bone scan, if clinically indicated
- Discuss sperm banking

CLINICAL STAGE^e

Stage IA, IB, IS

[See Primary Treatment \(TEST-7\)](#)

Stage IIA, IIB

[See Primary Treatment \(TEST-8\)](#)

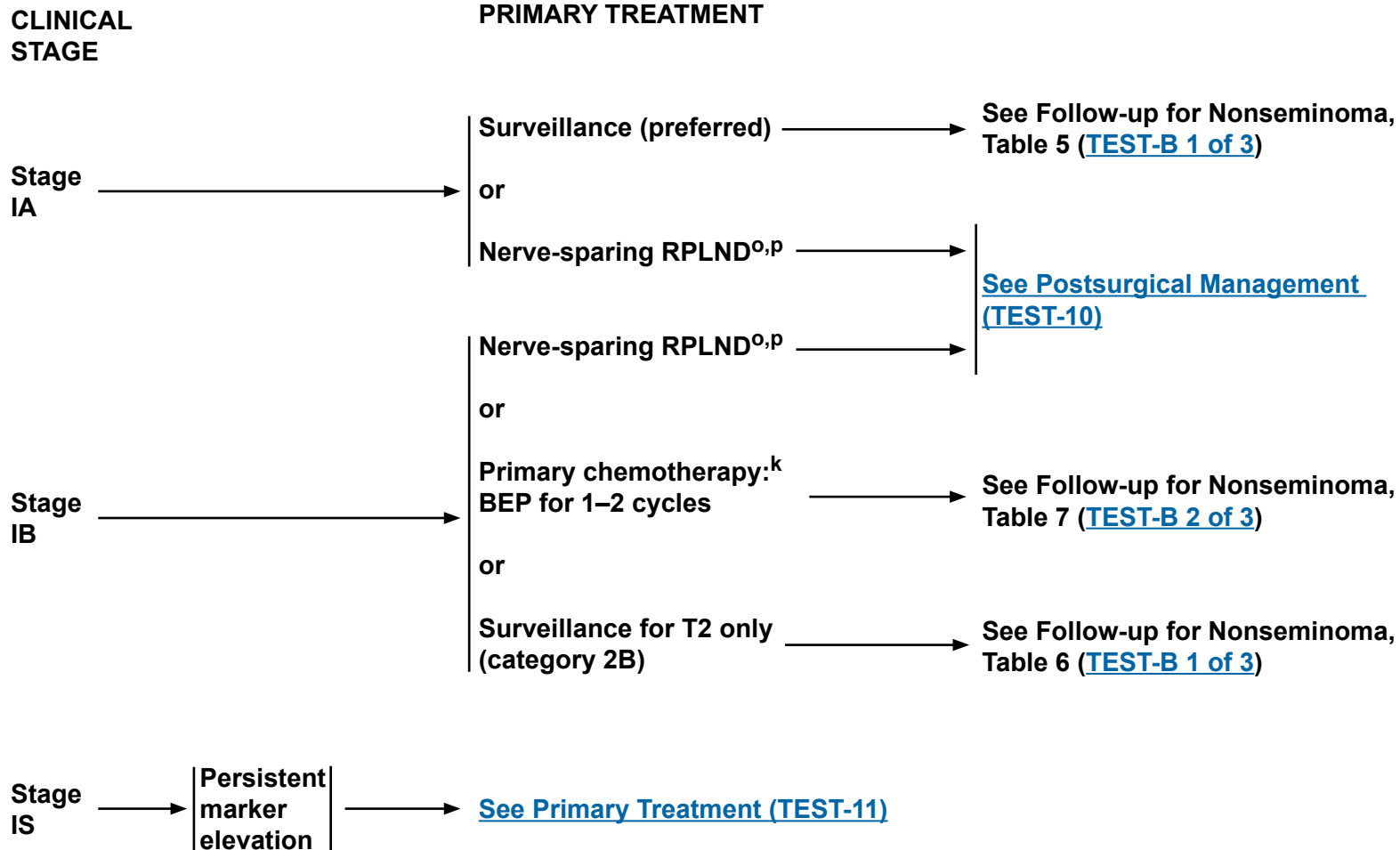
Stage IIC, IIIA, IIIB, IIIC, and brain metastasis

[See Primary Treatment \(TEST-11\)](#)

^eElevated values should be followed after orchiectomy with repeated determination to allow precise staging.

ⁿPET scan is not clinically indicated for nonseminoma.

Note: All recommendations are category 2A unless otherwise indicated.
Clinical Trials: NCCN believes that the best management of any cancer patient is in a clinical trial. Participation in clinical trials is especially encouraged.



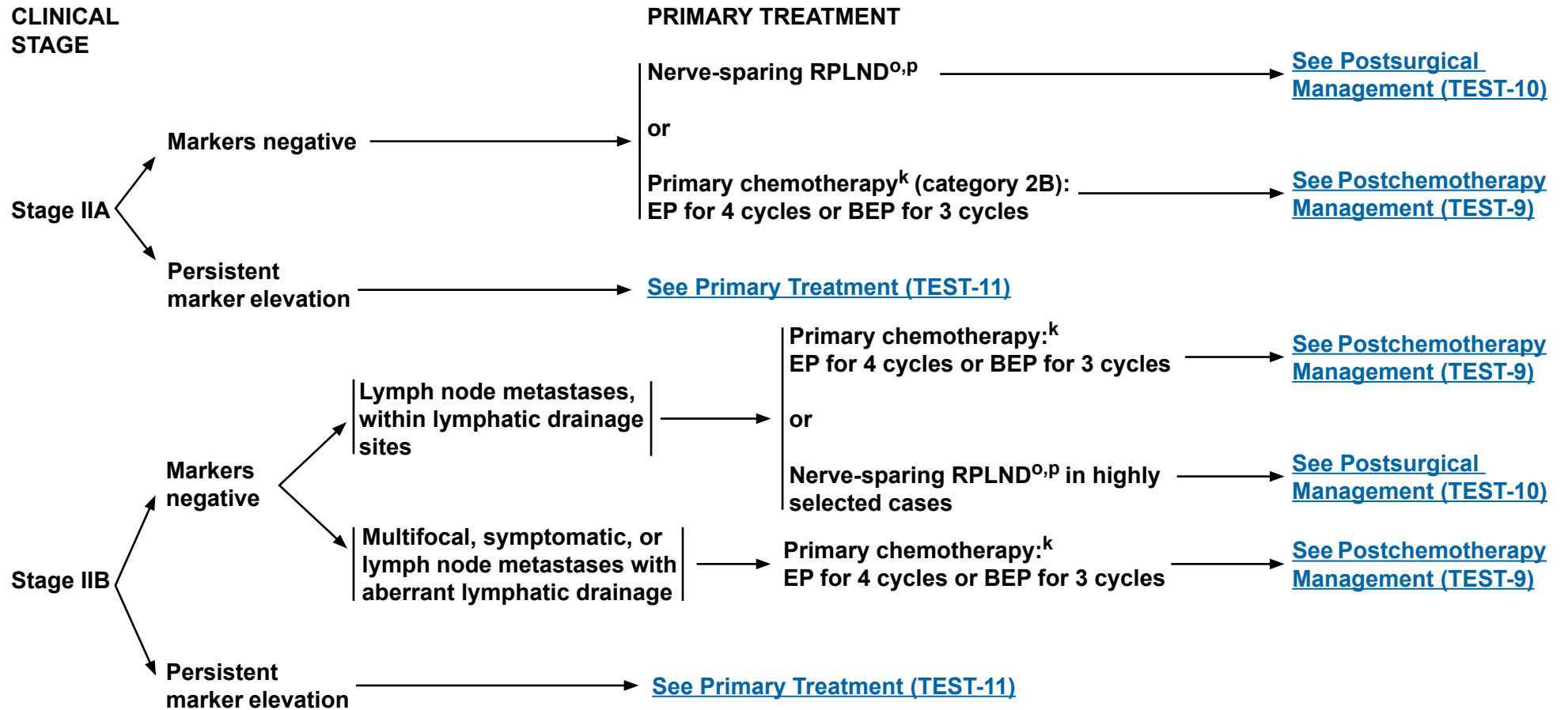
^k[See Primary Chemotherapy Regimens for Germ Cell Tumors \(TEST-E\).](#)

^oRetroperitoneal lymph node dissection (RPLND) is recommended within 4 weeks of CT scan and 7–10 days of markers.

^p[See Principles of Surgery for Germ Cell Tumors \(TEST-H\).](#)

Note: All recommendations are category 2A unless otherwise indicated.

Clinical Trials: NCCN believes that the best management of any cancer patient is in a clinical trial. Participation in clinical trials is especially encouraged.



EP = Etoposide/cisplatin
BEP = Bleomycin/etoposide/cisplatin

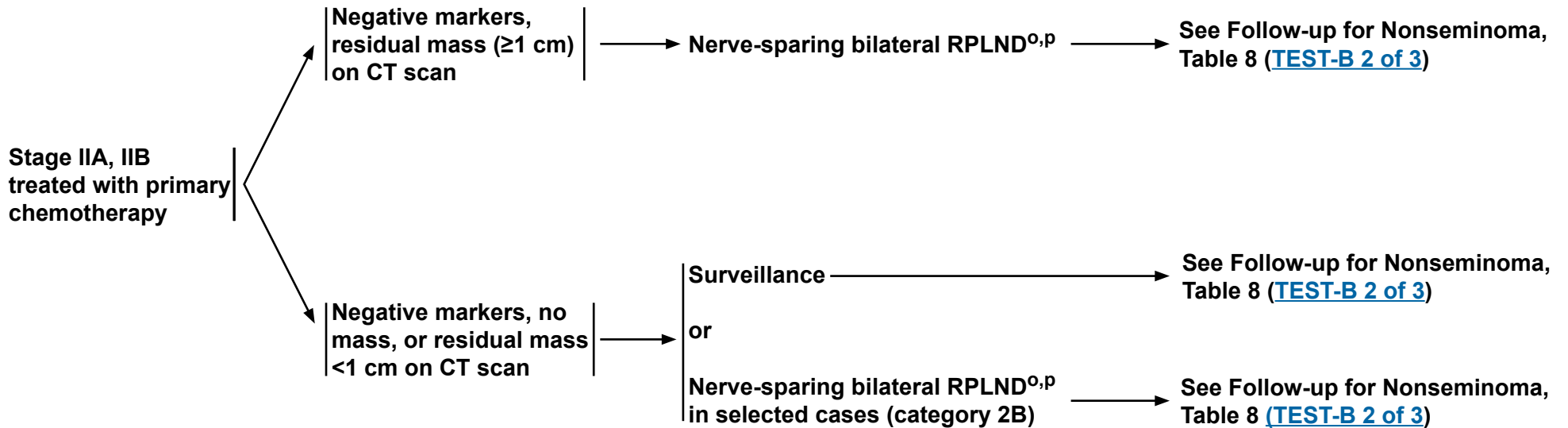
^kSee [Primary Chemotherapy Regimens for Germ Cell Tumors \(TEST-E\)](#).

^oRetroperitoneal lymph node dissection (RPLND) is recommended within 4 weeks of CT scan and 7–10 days of markers.

^pSee [Principles of Surgery for Germ Cell Tumors \(TEST-H\)](#).

Note: All recommendations are category 2A unless otherwise indicated.
Clinical Trials: NCCN believes that the best management of any cancer patient is in a clinical trial. Participation in clinical trials is especially encouraged.

POSTCHEMOTHERAPY MANAGEMENT

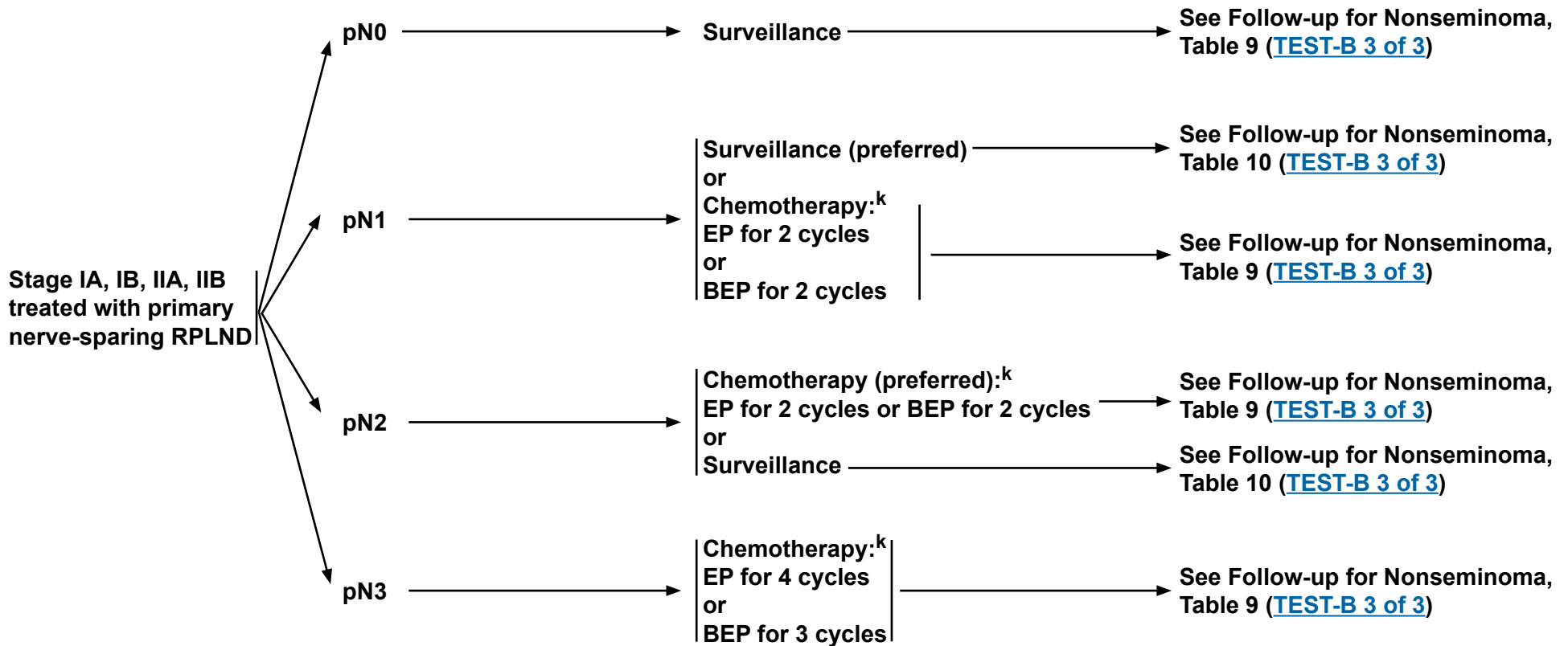


^oRetroperitoneal lymph node dissection (RPLND) is recommended within 4 weeks of CT scan and 7–10 days of markers.

^pSee [Principles of Surgery for Germ Cell Tumors \(TEST-H\)](#).

Note: All recommendations are category 2A unless otherwise indicated.
Clinical Trials: NCCN believes that the best management of any cancer patient is in a clinical trial. Participation in clinical trials is especially encouraged.

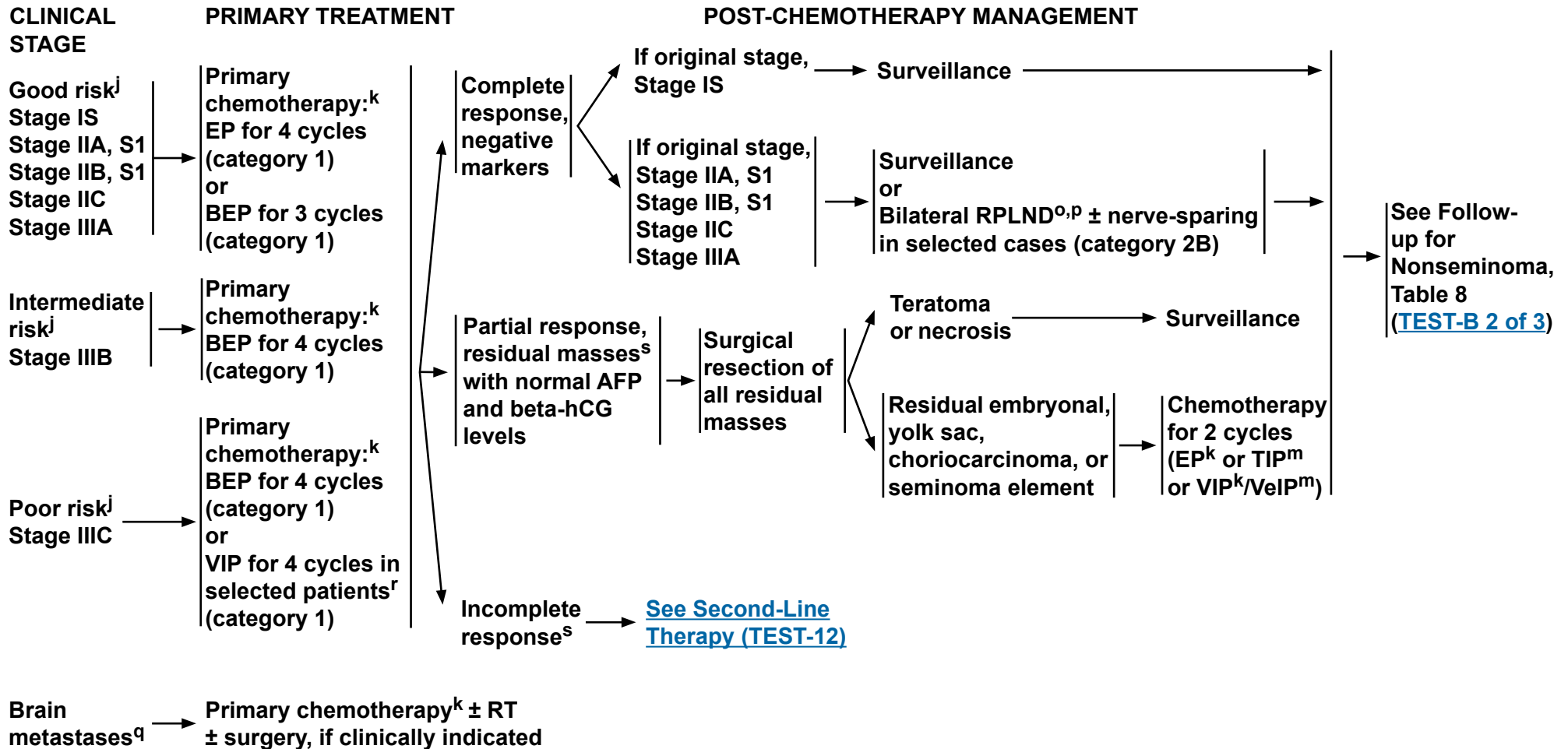
POSTSURGICAL MANAGEMENT



EP = Etoposide/cisplatin
BEP = Bleomycin/etoposide/cisplatin

^kSee Primary Chemotherapy Regimens for Germ Cell Tumors (TEST-E).

Note: All recommendations are category 2A unless otherwise indicated.
Clinical Trials: NCCN believes that the best management of any cancer patient is in a clinical trial. Participation in clinical trials is especially encouraged.



^oRetroperitoneal lymph node dissection (RPLND) is recommended within 4 weeks of CT scan and 7–10 days of markers.

^pSee Principles of Surgery for Germ Cell Tumors (TEST-H).

^qPatients should receive adequate treatment for brain metastases, in addition to cisplatin-based chemotherapy.

^rPatients who may not tolerate bleomycin.

^sThere is limited predictive value for PET scan for residual masses.

^jSee Risk Classification for Advanced Disease (TEST-D).

^kSee Primary Chemotherapy Regimens for Germ Cell Tumors (TEST-E).

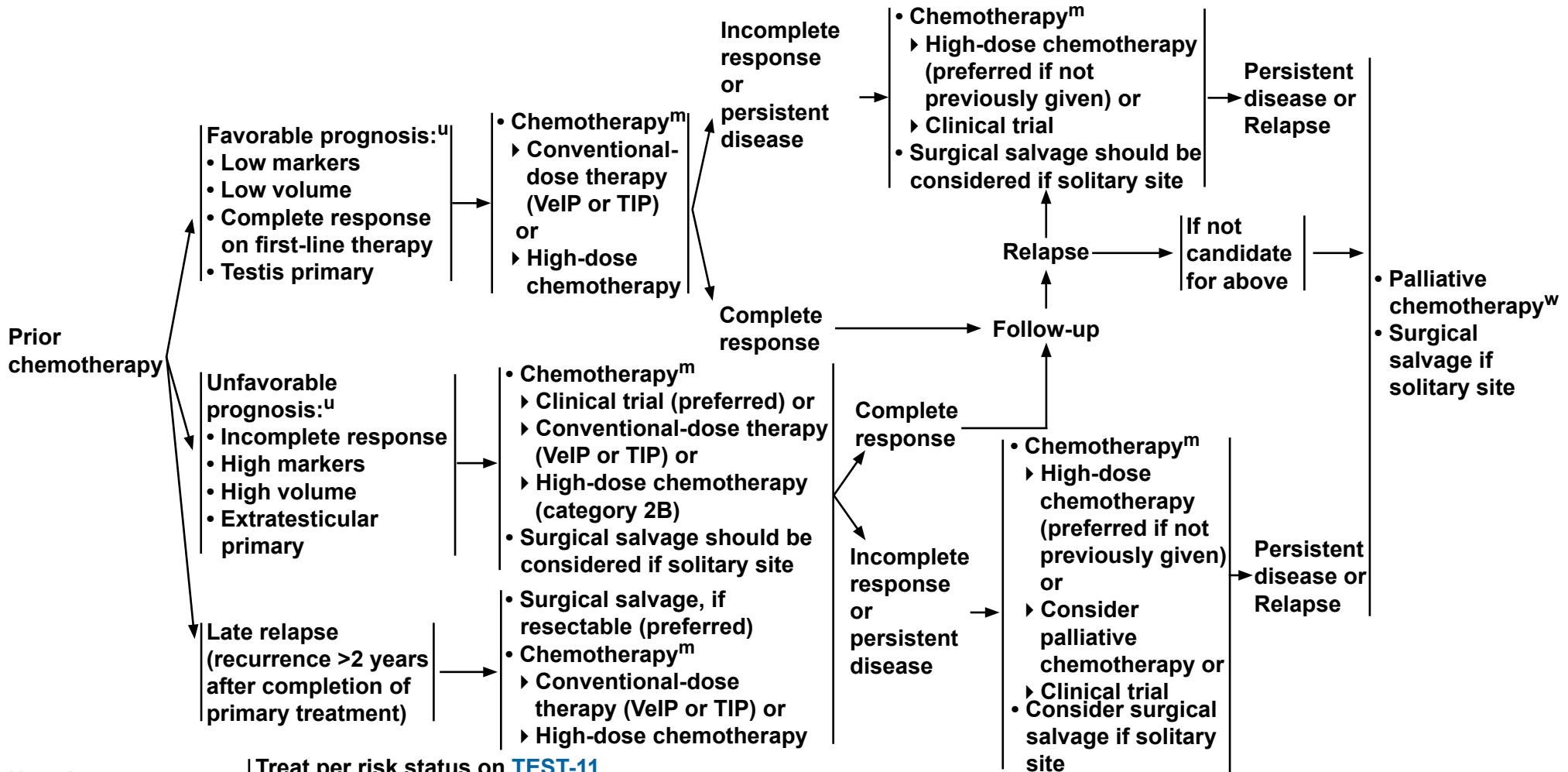
^mSee Second-Line Chemotherapy Regimens for Metastatic Germ Cell Tumors (TEST-F).

Note: All recommendations are category 2A unless otherwise indicated.

Clinical Trials: NCCN believes that the best management of any cancer patient is in a clinical trial. Participation in clinical trials is especially encouraged.

RECURRENCE†

SECOND-LINE THERAPY‡



^mSee [Second-Line Chemotherapy Regimens for Metastatic Germ Cell Tumors \(TEST-F\)](#).

†It is preferred that patients with recurrent nonseminoma be treated at centers with expertise in the management of this disease.

^uExamples of systems used to estimate prognosis are:

- 1) Lorch A, Beyer J, Bascoul-Mollevis C, et al. J Clin Oncol 2010;28:4906-4911.
- 2) Einhorn LH, Williams SD, Chalmers A, et al. New Engl J Med 2007;357:340-348.
- 3) Motzer RJ, Geller NL, Tan CC, et al. Cancer 1991;67:1305-1310.

^vIncludes best supportive care.

^wSee [Subsequent Chemotherapy Regimens for Metastatic Germ Cell Tumors \(TEST-G\)](#).

Note: All recommendations are category 2A unless otherwise indicated.

Clinical Trials: NCCN believes that the best management of any cancer patient is in a clinical trial. Participation in clinical trials is especially encouraged.

FOLLOW-UP FOR SEMINOMA

The follow-up for seminoma tables are to provide guidance, and should be modified for the individual patient based upon sites of disease, biology of disease, and length of time on treatment. Reassessment of disease activity should be performed in patients with new or worsening signs or symptoms of disease, regardless of the time interval from previous studies.

Table 1 Clinical Stage I Seminoma: Surveillance after Orchiectomy

	Year (at month intervals)				
	1	2	3	4	5
H&P ^{1,2}	Every 3–6 mo	Every 6–12 mo	Every 6–12 mo	Annually	Annually
Abdominal/ Pelvic CT	At 3, 6, and 12 mo	Every 6–12 mo	Every 6–12 mo	Every 12–24 mo	
Chest x-ray	As clinically indicated, consider chest CT in symptomatic patients.				

If Recurrence, treat according to extent of disease at relapse

Table 2 Clinical Stage I Seminoma: Surveillance after Adjuvant Treatment (Chemotherapy or Radiation)

	Year (at month intervals)				
	1	2	3	4	5
H&P ^{1,2}	Every 6–12 mo	Every 6–12 mo	Annually	Annually	Annually
Abdominal/ Pelvic CT	Annually	Annually	Annually	-----	
Chest x-ray	As clinically indicated, consider chest CT in symptomatic patients.				

If Recurrence, treat according to extent of disease at relapse

¹Serum tumor markers are optional.

²Testicular ultrasound for any equivocal exam.

Note: All recommendations are category 2A unless otherwise indicated.

Clinical Trials: NCCN believes that the best management of any cancer patient is in a clinical trial. Participation in clinical trials is especially encouraged.

FOLLOW-UP FOR SEMINOMA

Table 3 Clinical Stage IIA and Non-Bulky IIB Seminoma: Surveillance after Radiotherapy

	Year (at month intervals)				
	1	2	3	4	5
H&P^{1,2}	Every 3 mo	Every 6 mo	Every 6 mo	Every 6 mo	Every 6 mo
Abdominal/ Pelvic CT	At 3 mo, then at 6–12 mo	Annually	Annually	As clinically indicated	
Chest x-ray³	Every 6 mo	Every 6 mo	-----		

If Recurrence, treat according to extent of disease at relapse

Table 4 Bulky Clinical Stage IIB and Stage III Seminoma: Surveillance Post-Chemotherapy with No Residual Mass or Residual Mass ≤3 cm and Normal Tumor Markers

	Year (at month intervals)				
	1	2	3	4	5
H&P and markers²	Every 2 mo	Every 3 mo	Every 6 mo	Every 6 mo	Annually
Abdominal/ Pelvic CT⁴	• Abdominal/pelvic CT at 3–6 months, then as clinically indicated • PET scan as clinically indicated				
Chest x-ray³	Every 2 mo ⁵	Every 3 mo ⁵	Annually	Annually	Annually

If Recurrence, [see TEST-12](#).

¹Serum tumor markers optional.

²Testicular ultrasound for any equivocal exam.

³Chest x-ray may be used for routine follow-up but chest CT is preferred in the presence of thoracic symptoms.

⁴Patients with PET-negative residual mass measuring >3 cm following chemotherapy should undergo an abdominopelvic CT scan every 6 months for the first year then annually for five years.

⁵Add chest CT if supradiaphragmatic disease present at diagnosis.

Note: All recommendations are category 2A unless otherwise indicated.
Clinical Trials: NCCN believes that the best management of any cancer patient is in a clinical trial. Participation in clinical trials is especially encouraged.

FOLLOW-UP FOR NONSEMINOMA

The follow-up tables for nonseminoma are to provide guidance, and should be modified for the individual patient based upon sites of disease, biology of disease, and length of time on treatment. Reassessment of disease activity should be performed in patients with new or worsening signs or symptoms of disease, regardless of the time interval from previous studies.

Table 5 Clinical Stage IA, NSGCT: Active Surveillance

	Year (at month intervals)				
	1	2	3	4	5
H&P and markers ¹	Every 2 mo	Every 3 mo	Every 4–6 mo	Every 6 mo	Annually
Abdominal/ Pelvic CT	Every 4–6 mo	Every 6–12 mo	Annually	---	---
Chest x-ray ²	At mo 4 and 12	Annually	Annually	Annually	Annually

If Recurrence, see [TEST-12](#).

Table 6 Clinical Stage IB, NSGCT: Active Surveillance

	Year (at month intervals)				
	1	2	3	4	5
H&P and markers ¹	Every 2 mo	Every 3 mo	Every 4–6 mo	Every 6 mo	Annually
Abdominal/ Pelvic CT	Every 4 mo	Every 4–6 mo	Every 6 mo	Annually	---
Chest x-ray ²	Every 2 mo	Every 3 mo	Every 4–6 mo	Every 6 mo	Annually

If Recurrence, see [TEST-12](#).

¹Testicular ultrasound for any equivocal exam.

²Chest x-ray may be used for routine follow-up but chest CT is preferred in the presence of thoracic symptoms.

Note: All recommendations are category 2A unless otherwise indicated.

Clinical Trials: NCCN believes that the best management of any cancer patient is in a clinical trial. Participation in clinical trials is especially encouraged.

FOLLOW-UP FOR NONSEMINOMA

Table 7 Clinical Stage IB NSGCT: Treated with 1–2 Cycles of Adjuvant BEP Chemotherapy

	Year (at month intervals)				
	1	2	3	4	5
H&P and markers ¹	Every 3 mo	Every 3 mo	Every 6 mo	Every 6 mo	Annually
Abdominal/ Pelvic CT	Annually	Annually	---	---	---
Chest x-ray ²	Every 6–12 mo	Annually	---	---	---

If Recurrence, see [TEST-12](#).

Table 8 Clinical Stage II-III NSGCT: Surveillance After Complete Response to Chemotherapy ± Post-chemotherapy RPLND

	Year (at month intervals)				
	1	2	3	4	5
H&P and marker ¹	Every 2 mo	Every 3 mo	Every 6 mo	Every 6 mo	Every 6 mo
Abdominal/ Pelvic CT ³	Every 6 mo	Annually	---	---	---
Chest x-ray ^{2,4}	Every 6 mo	Every 6 mo	Annually ⁵	Annually ⁵	---

If Recurrence, see [TEST-12](#).

¹Testicular ultrasound for any equivocal exam.

²Chest x-ray may be used for routine follow-up but chest CT is preferred in the presence of thoracic symptoms.

³Patients who undergo RPLND and are found to have pN0 disease (no tumor or teratoma) need only 1 CT scan at postoperative month 4.

⁴Chest CT if supradiaphragmatic disease at baseline.

⁵Chest x-ray is optional at month 36 and 48.

Note: All recommendations are category 2A unless otherwise indicated.

Clinical Trials: NCCN believes that the best management of any cancer patient is in a clinical trial. Participation in clinical trials is especially encouraged.

FOLLOW-UP FOR NONSEMINOMA

Table 9 Pathologic Stage IIA/B NSGCT: Post-Primary RPLND and Treated with Adjuvant Chemotherapy

	Year (at month intervals)				
	1	2	3	4	5
H&P and markers ¹	Every 6 mo	Every 6 mo	Annually	Annually	Annually
Abdominal/ Pelvic CT	After RPLND	As clinically indicated			
Chest x-ray ²	Every 6 mo	Annually	Annually	Annually	Annually

If Recurrence, see [TEST-12](#).

Table 10 Pathologic Stage IIA/B NSGCT: Post-Primary RPLND and **NOT** Treated with Adjuvant Chemotherapy⁶

	Year (at month intervals)				
	1	2	3	4	5
H&P and markers ¹	Every 2 mo	Every 3 mo	Every 4 mo	Every 6 mo	Annually
Abdominal/ Pelvic CT	At 3–4 mo ⁷	As clinically indicated			
Chest x-ray ²	Every 2–4 mo	Every 3–6 mo	Annually	Annually	Annually

If Recurrence, see [TEST-12](#).

¹Testicular ultrasound for any equivocal exam.

²Chest x-ray may be used for routine follow-up but chest CT is preferred in the presence of thoracic symptoms.

⁶Patients with clinical stage II-A/II-B nonseminoma who undergo primary RPLND and are found to have pN0 disease (no tumor or teratoma, pathologic Stage I) should revert to the surveillance schedule for low-risk NSGCT with the exception that only 1 CT scan is needed postoperatively around month 4 (Table 5).

⁷This schedule assumes a complete resection has taken place.

Note: All recommendations are category 2A unless otherwise indicated.

Clinical Trials: NCCN believes that the best management of any cancer patient is in a clinical trial. Participation in clinical trials is especially encouraged.

PRINCIPLES OF RADIOTHERAPY FOR PURE TESTICULAR SEMINOMA

General Principles

- Modern radiotherapy involves smaller fields and lower doses than were used in the past. References are provided to support current recommended management.
- Risk-adapted management using tumor size >4 cm and rete testis invasion for stage I seminoma is discouraged. This is based on a validation study in 2010, which revealed that tumor size >4 cm and rete testis invasion were not predictors of relapse.^{1,2}
- Linear accelerators with >6 MV photons should be used when possible.
- The mean dose (D_{mean}) and dose delivered to 50% of the volume (D_{50%}) of the kidneys, liver, and bowel are lower with CT-based anteroposterior-posteroanterior (AP-PA) three-dimensional conformal radiation therapy (3D-CRT) than intensity-modulated radiation therapy (IMRT).³ As a result, the risk of second cancers arising in the kidneys, liver, or bowel may be lower with 3D-CRT than IMRT, and IMRT is not recommended.⁴
- Timing of Radiotherapy:
 - ▶ Radiotherapy should start once the orchiectomy wound has fully healed.
 - ▶ Patients should be treated 5 days per week.
 - ▶ Patients who miss a fraction should be treated to the same total dose and with the same fraction size, extending the overall treatment time slightly.
- Antiemetic medication significantly improves nausea. [See the NCCN Guidelines for Antiemesis](#). Antiemetic prophylaxis is encouraged at least two hours prior to each treatment, and some cases may require more frequent dosing.

Preparation for Radiotherapy

- A discussion of semen analysis and sperm banking prior to orchiectomy is recommended in patients who wish to preserve fertility.^{5,6} If sperm banking is desired, it should be performed prior to imaging and the delivery of adjuvant therapy.

Treatment Planning Principles

- A non-contrast CT simulation should be performed with the patient supine, arms at his sides, in the treatment position.
 - ▶ Immobilization with a cast may be used to improve the reproducibility of patient setup.
 - ▶ All patients, with the exception of those who have undergone bilateral orchiectomy, should be treated with a scrotal shield. The legs should be separated by a rolled towel of approximately the same diameter as the scrotal shield and its stand.

[For Stage I, see TEST-C 2 of 5](#)

[For Stage IIA, IIB, see TEST-C 3 of 5](#)

[For References, see TEST-C 5 of 5](#)

Note: All recommendations are category 2A unless otherwise indicated.

Clinical Trials: NCCN believes that the best management of any cancer patient is in a clinical trial. Participation in clinical trials is especially encouraged.

PRINCIPLES OF RADIOTHERAPY FOR PURE TESTICULAR SEMINOMA

Stage I

- **Dose:** For stages IA, IB, and IS, a total dose of 20.0 Gy (midplane) in 10 fractions. Daily 2.0-Gy is recommended for the minority of patients who prefer adjuvant treatment, realizing that there is a high likelihood of salvage should a relapse occur during surveillance.⁹
- **Para-aortic (PA)-Strip Fields¹⁰ - Field Arrangement:**
 - ▶ In patients with no history of pelvic or scrotal surgery, para-aortic strip irradiation may be delivered with opposed AP-PA fields. The weights of the fields may be equal.
 - ◇ Recent nodal mapping studies suggest that fields should target the retroperitoneal lymph nodes but not necessarily the ipsilateral renal hilar nodes (see Lateral borders).^{11,12}
 - ◇ Superior and inferior borders: Borders may be determined by bony anatomy.
 - The superior border should be placed at the bottom of vertebral body T-11.¹³
 - The inferior border should be placed at the inferior border of vertebral body L-5.^{10,14}
 - ◇ Lateral borders:
 - Conventionally, PA-strip fields are approximately 10 cm wide, encompassing the tips of the transverse processes of the PA vertebrae.
 - The location of the kidneys within the PA-strip fields varies from patient to patient.
 - For patients whose kidneys are relatively medial, small renal blocks may be added at the level of T-12. The right and left kidney D50% should be ≤ 8 Gy (ie, no more than 50% of each kidney can receive 8 Gy or higher).³ If only one kidney is present, the kidney D15% should be ≤ 20 Gy (ie, no more than 15% of the volume of the kidney can receive 20 Gy or higher).³
 - An alternative 3D-CRT planning technique is to base the lateral borders on vascular structures on a treatment planning CT scan without contrast. The aorta and inferior vena cava may be contoured on the CT scan; one should allow a 1.2-1.9-cm margin on the aorta and inferior vena cava to include the para-aortic, paracaval, interaortocaval, and preaortic nodes in the clinical target volume.^{11,15} The planning target volume is then established by uniformly expanding the clinical target volume by 0.5 cm in all directions to account for treatment setup errors.¹⁶ A uniform 0.7 cm margin should be provided on the planning target volume to the block edge to take beam penumbra into account (Figure 1, [see TEST-C 4 of 5](#)).³

Special Considerations:

- Ipsilateral pelvic surgery (eg, inguinal herniorrhaphy or orchiopexy) may alter the lymphatic drainage of the testis. As a result, irradiation of the ipsilateral iliac and inguinal lymph nodes, including the surgical scar from prior surgery, has been advocated even in stage I patients.^{12,17} Given the large volume of tissue that would be irradiated and the resulting increased risks of late effects, other management approaches are recommended for these patients.

[For Stage IIA, IIB, see TEST-C 3 of 5](#)
[For References, see TEST-C 5 of 5](#)

Note: All recommendations are category 2A unless otherwise indicated.

Clinical Trials: NCCN believes that the best management of any cancer patient is in a clinical trial. Participation in clinical trials is especially encouraged.

PRINCIPLES OF RADIOTHERAPY FOR PURE TESTICULAR SEMINOMA

Stage IIA-IIB

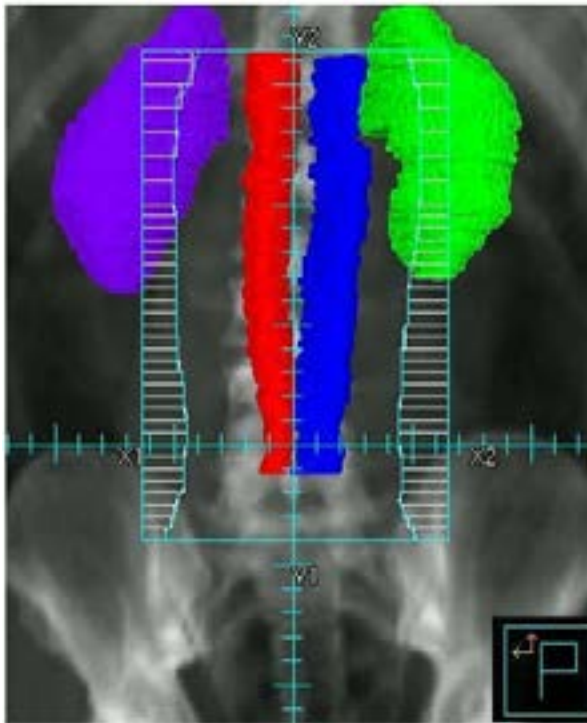
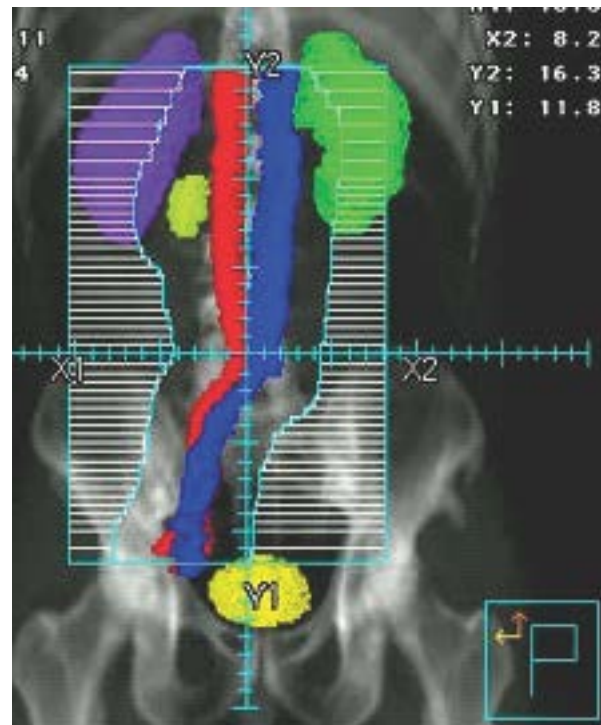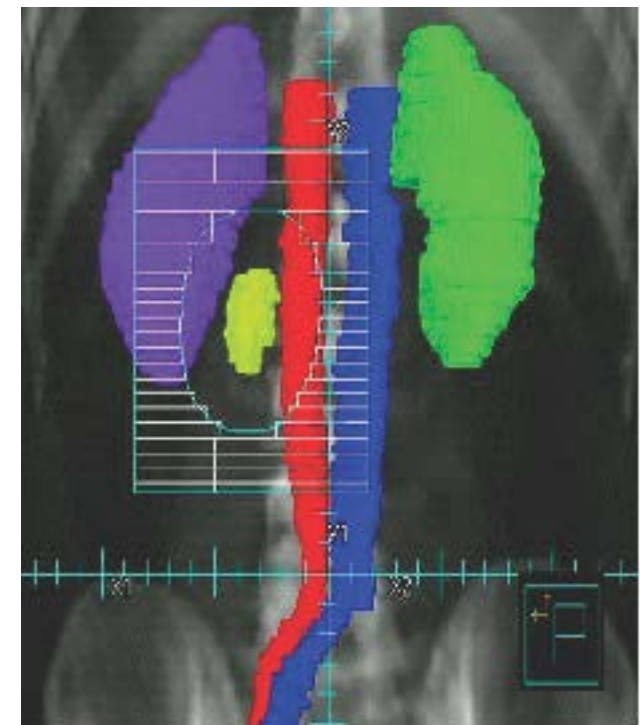
- Patients should not receive primary RT if they have a horseshoe (pelvic) kidney, inflammatory bowel disease, or a history of RT.
- For clinical stage IIA-B patients, treatment is delivered in two consecutive AP-PA phases (modified dog-leg fields and cone down). There is no break between the 2 phases.
- **Modified Dog-Leg Fields:**
 - ▶ **Dose:** The initial phase consists of treatment of modified dog-leg fields to 20.0 Gy (midplane) in 10 fractions; daily 2.0-Gy¹⁷.
 - ▶ **Target:** The fields should include the retroperitoneal and proximal ipsilateral iliac lymph nodes.
 - ◊ **Modified dog-leg fields as described by Classen et al are preferred.**¹⁸
 - Care should be taken to ensure coverage of the ipsilateral common, external, and proximal internal iliac lymph nodes down to the top of the acetabulum.
 - The fields can be set up using bony landmarks or by contouring the vascular structures, as for stage I.
 - The superior border should be placed at the bottom of vertebral body T-11.¹⁹
 - The inferior border should be placed at the top of the acetabulum.¹⁸
 - The medial border for the lower aspect of the modified dog-leg fields extends from the tip of the contralateral transverse process of the fifth lumbar vertebra toward the medial border of the ipsilateral obturator foramen.
 - The lateral border for the lower aspect of the modified dog-leg fields is defined by a line from the tip of the ipsilateral transverse process of the fifth lumbar vertebra to the superolateral border of the ipsilateral acetabulum.
 - Preferably, one should contour the aorta and inferior vena cava from the bottom of the T-11 vertebra inferiorly and ipsilateral iliac arteries and veins down to the top of the acetabulum. One should provide a 1.2- to 1.9-cm margin on these vascular structures for the clinical target volume.^{11,15} The planning target volume is then established by uniformly expanding the clinical target volume by 0.5 cm in all directions to account for treatment setup errors.¹⁶ A uniform 0.7 cm margin should be provided on the planning target volume to the block edge to take beam penumbra into account (Figure 2, [see TEST-C 4 of 5](#)).³
 - It is not necessary to include the ipsilateral inguinal nodes or the inguinal scar in the AP-PA fields unless the patient has a history of ipsilateral pelvic surgery (eg, inguinal herniorrhaphy or orchiopexy).
- **Cone Down:**
 - ▶ **Dose:** The second phase (cone down) of the radiotherapy consists of daily 2-Gy fractions to a cumulative total dose of approximately 30 Gy for stage IIA and 36 Gy for stage IIB.¹⁸
 - ▶ **Target:** The nodal mass (gross tumor volume) must be contoured. A uniform, 2-cm margin from the gross tumor volume to block edge should be provided for the AP-PA cone down fields (Figure 3, [see TEST-C 4 of 5](#)).

[For Stage I, see TEST-C 2 of 5](#)

[For References, see TEST-C 5 of 5](#)

Note: All recommendations are category 2A unless otherwise indicated.

Clinical Trials: NCCN believes that the best management of any cancer patient is in a clinical trial. Participation in clinical trials is especially encouraged.

PRINCIPLES OF RADIOTHERAPY FOR PURE TESTICULAR SEMINOMA**Figure 1****Figure 2****Figure 3**

[For Stage I, see TEST-C 2 of 5](#)
[For Stage IIA, IIB, see TEST-C 3 of 5](#)
[For References, see TEST-C 5 of 5](#)

Note: All recommendations are category 2A unless otherwise indicated.

Clinical Trials: NCCN believes that the best management of any cancer patient is in a clinical trial. Participation in clinical trials is especially encouraged.

PRINCIPLES OF RADIOTHERAPY FOR PURE TESTICULAR SEMINOMA

References

1. Chung P, Warde P. Stage I seminoma: adjuvant treatment is effective but is it necessary? *J Natl Cancer Inst* 2011;103:194-196.
2. Chung P: Prognostic factors for relapse in stage I seminoma: A validation study [abstract]. *J Clin Oncol* 2010;28: Abstract 4535.
3. Zilli T, Boudreau C, Doucet R, et al. Bone marrow-sparing intensity-modulated radiation therapy for Stage I seminoma. *Acta Oncol* 2011;50:555-562.
4. Hall EJ, Wu CS. Radiation-induced second cancers: the impact of 3D-CRT and IMRT. *Int J Radiat Oncol Biol Phys* 2003;56:83-88.
5. Ragni G, Somigliana E, Restelli L, et al. Sperm banking and rate of assisted reproduction treatment: insights from a 15-year cryopreservation program for male cancer patients. *Cancer* 2003;97:1624-1629.
6. Saito K, Suzuki K, Iwasaki A, et al. Sperm cryopreservation before cancer chemotherapy helps in the emotional battle against cancer. *Cancer* 2005;104:521-524.
7. Oliver RT, Mead GM, Rustin GJ, et al. Randomized trial of carboplatin versus radiotherapy for stage I seminoma: mature results on relapse and contralateral testis cancer rates in MRC TE19/EORTC 30982 study (ISRCTN27163214). *J Clin Oncol* 2011;29:957-962.
8. Mead GM, Fossa SD, Oliver RT, et al. Randomized trials in 2466 patients with stage I seminoma: patterns of relapse and follow-up. *J Natl Cancer Inst* 2011;103:241-249.
9. Garmezly B, Pagliaro LC. Choosing treatment for stage I seminoma: who should get what? *Oncology (Williston Park)* 2009;23:753-759.
10. Fossa SD, Horwich A, Russell JM, et al. Optimal planning target volume for stage I testicular seminoma: A Medical Research Council randomized trial. Medical Research Council Testicular Tumor Working Group. *J Clin Oncol* 1999;17:1146-1154.
11. Dinniwell R, Chan P, Czarnota G, et al. Pelvic lymph node topography for radiotherapy treatment planning from ferumoxtran-10 contrast-enhanced magnetic resonance imaging. *Int J Radiat Oncol Biol Phys* 2009;74:844-851.
12. McMahon CJ, Rofsky NM, Pedrosa I. Lymphatic metastases from pelvic tumors: anatomic classification, characterization, and staging. *Radiology* 2010;254:31-46.
13. Bruns F, Bremer M, Meyer A, et al. Adjuvant radiotherapy in stage I seminoma: is there a role for further reduction of treatment volume? *Acta Oncol* 2005;44:142-148.
14. Classen J, Schmidberger H, Meisner C, et al. Para-aortic irradiation for stage I testicular seminoma: results of a prospective study in 675 patients. A trial of the German testicular cancer study group (GTCSG). *Br J Cancer* 2004;90:2305-2311.
15. Shih HA, Harisinghani M, Zietman AL, et al. Mapping of nodal disease in locally advanced prostate cancer: rethinking the clinical target volume for pelvic nodal irradiation based on vascular rather than bony anatomy. *Int J Radiat Oncol Biol Phys* 2005;63:1262-1269.
16. Boujelbene N, Cosinschi A, Khanfir K, et al. Pure seminoma: a review and update. *Radiat Oncol* 2011;6:90.
17. Jones WG, Fossa SD, Mead GM, et al. Randomized trial of 30 versus 20 Gy in the adjuvant treatment of stage I Testicular Seminoma: a report on Medical Research Council Trial TE18, European Organisation for the Research and Treatment of Cancer Trial 30942 (ISRCTN18525328). *J Clin Oncol* 2005;23:1200-1208.
18. Classen J, Schmidberger H, Meisner C, et al. Radiotherapy for stages IIA/B testicular seminoma: final report of a prospective multicenter clinical trial. *J Clin Oncol* 2003;21:1101-1106.
19. Paly JJ, Efstathiou JA, Hedgire SS, et al. Mapping patterns of nodal metastases in seminoma: rethinking radiotherapy fields. *Radiother Oncol* 2013;106:64-68.

Note: All recommendations are category 2A unless otherwise indicated.

Clinical Trials: NCCN believes that the best management of any cancer patient is in a clinical trial. Participation in clinical trials is especially encouraged.

RISK CLASSIFICATION FOR ADVANCED DISEASE
(post-orchietomy)¹

Risk Status	Nonseminoma	Seminoma
Good Risk	Testicular or retroperitoneal primary tumor and No nonpulmonary visceral metastases and Post-orchietomy markers- all of: AFP < 1,000 ng/mL hCG < 5,000 iu/L LDH < 1.5 x upper limit of normal	Any primary site and No nonpulmonary visceral metastases and Normal AFP Any hCG Any LDH
Intermediate Risk	Testicular or retroperitoneal primary tumor and No nonpulmonary visceral metastases and Post-orchietomy markers- any of: AFP 1,000–10,000 ng/mL hCG 5,000–50,000 iu/L LDH 1.5–10 x upper limit of normal	Any primary site and Nonpulmonary visceral metastases and Normal AFP Any hCG Any LDH
Poor Risk	Mediastinal primary tumor or Nonpulmonary visceral metastases or Post-orchietomy markers- any of: AFP > 10,000 ng/mL hCG > 50,000 iu/L LDH > 10 x upper limit of normal	No patients classified as poor prognosis

Source: Figure 4 from the International Germ Cell Cancer Collaborative Group: International Germ Cell Consensus Classification: A Prognostic Factor-Based Staging System for Metastatic Germ Cell Cancers. J Clin Oncol 1997;15(2):594-603. Reprinted with permission of the American Society of Clinical Oncology.

¹Markers used for risk classification are post-orchietomy.

Note: All recommendations are category 2A unless otherwise indicated.
Clinical Trials: NCCN believes that the best management of any cancer patient is in a clinical trial. Participation in clinical trials is especially encouraged.

**PRIMARY CHEMOTHERAPY REGIMENS
FOR GERM CELL TUMORS**

EP

Etoposide 100 mg/m² IV on Days 1–5
Cisplatin 20 mg/m² IV on Days 1–5
Repeat every 21 days¹

BEP

Etoposide 100 mg/m² IV on Days 1–5
Cisplatin 20 mg/m² IV on Days 1–5
Bleomycin 30 units IV weekly on Days 1, 8, and 15 or Days 2, 9, and 16
Repeat every 21 days²

VIP

Etoposide 75 mg/m² IV on Days 1–5
Mesna 120 mg/m² slow IV Push before ifosfamide on Day 1, then
Mesna 1200 mg/m² IV Continuous Infusion on Days 1–5
Ifosfamide 1200 mg/m² on Days 1–5
Cisplatin 20 mg/m² IV on Days 1–5
Repeat every 21 days³

¹Xiao H, Mazumdar M, Bajorin DF, et al. Long-term follow-up of patients with good-risk germ cell tumors treated with etoposide and cisplatin. J Clin Oncol 1997;15:2553-2558.

²Saxman SB, Finch D, Gonin R & Einhorn LH. Long-term follow-up of a phase III study of three versus four cycles of bleomycin, etoposide, and cisplatin in favorable-prognosis germ-cell tumors: The Indiana University Experience. J Clin Oncol 1998;16:702-706.

³Nichols CR, Catalano PJ, Crawford ED, et al. Randomized comparison of cisplatin and etoposide and either bleomycin or ifosfamide in treatment of advanced disseminated germ cell tumors: An Eastern Cooperative Oncology Group, Southwest Oncology Group, and Cancer and Leukemia Group B Study. J Clin Oncol 1998;16:1287-1293.

Note: All recommendations are category 2A unless otherwise indicated.

Clinical Trials: NCCN believes that the best management of any cancer patient is in a clinical trial. Participation in clinical trials is especially encouraged.

SECOND-LINE CHEMOTHERAPY REGIMENS FOR METASTATIC GERM CELL TUMORS

Conventional-Dose Chemotherapy Regimens

VeIP

Vinblastine 0.11 mg/kg IV Push on Days 1–2
Mesna 400 mg/m² IV every 8 hours on Days 1–5
Ifosfamide 1200 mg/m² IV on Days 1–5
Cisplatin 20 mg/m² IV on Days 1–5
Repeat every 21 days¹

TIP

Paclitaxel 250 mg/m² IV on Day 1
Ifosfamide 1500 mg/m² IV on Days 2–5
Mesna 500 mg/m² IV before ifosfamide, and then 4 and 8 hours after each ifosfamide dose on Days 2–5
Cisplatin 25 mg/m² IV on Days 2–5
Repeat every 21 days²

High-Dose Chemotherapy Regimens

Carboplatin 700 mg/m² (body surface area) IV
Etoposide 750 mg/m² IV
Administer 5, 4, and 3 days before peripheral blood stem cell infusion for 2 cycles³

Paclitaxel 200 mg/m² IV over 24 hours on Day 1
Ifosfamide 2000 mg/m² over 4 hours with mesna protection on Days 2–4
Repeat every 14 days for 2 cycles followed by
Carboplatin AUC 7–8 IV over 60 minutes Days 1–3
Etoposide 400 mg/m² IV Days 1–3
Administer with peripheral blood stem cell support at 14- to 21-day intervals for 3 cycles⁴

¹Loehrer PJ Sr, Lauer R, Roth BJ, et al. Salvage therapy in recurrent germ cell cancer: ifosfamide and cisplatin plus either vinblastine or etoposide. *Ann Intern Med* 1988;109:540-546.

²Kondagunta GV, Bacik J, Donadio A, et al. Combination of paclitaxel, ifosfamide, and cisplatin is an effective second-line therapy for patients with relapsed testicular germ cell tumors. *J Clin Oncol* 2005;23:6549-6555.

³Einhorn LH, Williams SD, Chamness A, et al. High-dose chemotherapy and stem-cell rescue for metastatic germ-cell tumors. *N Engl J Med* 2007;357:340-348.

⁴Feldman DR, Sheinfeld J, Bajorin DF et al. TI-CE high-dose chemotherapy for patients with previously treated germ cell tumors: results and prognostic factor analysis. *J Clin Oncol* 2010;28:1706-1713.

Note: All recommendations are category 2A unless otherwise indicated.

Clinical Trials: NCCN believes that the best management of any cancer patient is in a clinical trial. Participation in clinical trials is especially encouraged.



SUBSEQUENT CHEMOTHERAPY REGIMENS FOR METASTATIC GERM CELL TUMORS

Palliative Chemotherapy Regimens*

Gemcitabine/oxaliplatin

Gemcitabine/paclitaxel

Gemcitabine/paclitaxel/oxaliplatin

Etoposide (oral)

*See references below for dosing.

Etoposide (oral)

Miller JC, Einhorn LH. Phase II study of daily oral etoposide in refractory germ cell tumors. *Semin Oncol* 1990;17:36-39.

Gemcitabine/oxaliplatin

Pectasides D, Pectasides M, Farmakis D, et al. Gemcitabine and oxaliplatin (GEMOX) in patients with cisplatin-refractory germ cell tumors: a phase II study. *Ann Oncol* 2004;15:493-497.

Kollmannsberger C, Beyer J, Liersch R, et al. Combination chemotherapy with gemcitabine plus oxaliplatin in patients with intensively pretreated or refractory germ cell cancer: A study of the German Testicular Cancer Study Group. *J Clin Oncol* 2004;22:108-114.

De Giorgi U, Rosti G, Aieta M, et al. Phase II study of oxaliplatin and gemcitabine salvage chemotherapy in patients with cisplatin-refractory nonseminomatous germ cell tumor. *Eur Urol* 2006;50:893-894.

Paclitaxel/gemcitabine

Einhorn LH, Brames MJ, Juliar B, Williams SD. Phase II study of paclitaxel plus gemcitabine salvage chemotherapy for germ cell tumors after progression following high-dose chemotherapy with tandem transplant. *J Clin Oncol* 2007;25:513-516.

Mulherin B, Brames M, Einhorn L. Long-term survival with paclitaxel and gemcitabine for germ cell tumors after progression following high-dose chemotherapy with tandem transplants [abstract]. *J Clin Oncol* 2011;29:Abstract 4562.

Gemcitabine/oxaliplatin/paclitaxel

Bokemeyer C, Oechsle K, Honecker F, Mayer F, Hartmann JT, Waller CF, Böhlke I, Kollmannsberger C; German Testicular Cancer Study Group. Combination chemotherapy with gemcitabine, oxaliplatin, and paclitaxel in patients with cisplatin-refractory or multiply relapsed germ-cell tumors: A study of the German Testicular Cancer Study Group. *Ann Oncol* 2008;19:448-453.

Note: All recommendations are category 2A unless otherwise indicated.

Clinical Trials: NCCN believes that the best management of any cancer patient is in a clinical trial. Participation in clinical trials is especially encouraged.

**PRINCIPLES OF SURGERY
FOR GERM CELL TUMORS**

- RPLND is the standard approach to the surgical management of NSGCTs in both the primary and post-chemotherapy setting.
- A template dissection or a nerve-sparing approach to minimize the risk of ejaculatory disorders should be considered in patients undergoing primary RPLND for stage I nonseminoma.
- The “split and roll” technique in which lumbar vessels are identified and sequentially ligated allows resection of all lymphatic tissue around and behind the great vessels (ie, aorta, IVC) and minimizes the risk of an in-field recurrence.

Post-Chemotherapy Setting

- Referral to high-volume centers should be considered for surgical resection of masses post-chemotherapy.
- Completeness of resection is an independent and consistent predictive variable of clinical outcome. In post-chemotherapy RPLND, surgical margins should not be compromised in an attempt to preserve ejaculation. Additional procedures and resection of adjacent structures may be required.
- Post-chemotherapy RPLND is indicated in metastatic NSGCT patients with a residual retroperitoneal mass following systemic chemotherapy and normalized post-chemotherapy serum tumor markers.
- A full bilateral template RPLND should be performed in all patients undergoing RPLND in the post-chemotherapy setting, with the boundaries of dissection being the renal hilar vessels (superiorly), ureters (laterally), and the common iliac arteries (inferiorly).

Note: All recommendations are category 2A unless otherwise indicated.

Clinical Trials: NCCN believes that the best management of any cancer patient is in a clinical trial. Participation in clinical trials is especially encouraged.

Table 1

**American Joint Committee on Cancer (AJCC)
TNM Staging System for Testis Cancer (7th ed., 2010)**

Primary Tumor (T)*

The extent of primary tumor is usually classified after radical orchiectomy, and for this reason, a pathologic stage is assigned.

- pTX Primary tumor cannot be assessed
- pT0 No evidence of primary tumor (e.g. histologic scar in testis)
- pTis Intratubular germ cell neoplasia (carcinoma in situ)
- pT1 Tumor limited to the testis and epididymis without vascular/lymphatic invasion; tumor may invade into the tunica albuginea but not the tunica vaginalis
- pT2 Tumor limited to the testis and epididymis with vascular/lymphatic invasion, or tumor extending through the tunica albuginea with involvement of the tunica vaginalis
- pT3 Tumor invades the spermatic cord with or without vascular/lymphatic invasion
- pT4 Tumor invades the scrotum with or without vascular/lymphatic invasion

*Note: Except for pTis and pT4, extent of primary tumor is classified by radical orchiectomy. TX may be used for other categories in the absence of radical orchiectomy.

Used with the permission of the American Joint Committee on Cancer (AJCC), Chicago, Illinois. The original and primary source for this information is the AJCC Cancer Staging Manual, Seventh Edition (2010) published by Springer Science+Business Media, LLC (SBM). (For complete information and data supporting the staging tables, visit www.springer.com.) Any citation or quotation of this material must be credited to the AJCC as its primary source. The inclusion of this information herein does not authorize any reuse or further distribution without the expressed, written permission of Springer SBM, on behalf of the AJCC.

Regional Lymph Nodes (N)

Clinical

- NX Regional lymph nodes cannot be assessed
- N0 No regional lymph node metastasis
- N1 Metastasis with a lymph node mass 2 cm or less in greatest dimension; or multiple lymph nodes, none more than 2 cm in greatest dimension
- N2 Metastasis with a lymph node mass, more than 2 cm but not more than 5 cm in greatest dimension; or multiple lymph nodes, any one mass greater than 2 cm but not more than 5 cm in greatest dimension
- N3 Metastasis with a lymph node mass more than 5 cm in greatest dimension

Pathologic (pN)

- pNX Regional lymph nodes cannot be assessed
- pN0 No regional lymph node metastasis
- pN1 Metastasis with a lymph node mass 2 cm or less in greatest dimension and less than or equal to five nodes positive, none more than 2 cm in greatest dimension
- pN2 Metastasis with a lymph node mass more than 2 cm but not more than 5 cm in greatest dimension; or more than five nodes positive, none more than 5 cm; or evidence of extranodal extension of tumor
- pN3 Metastasis with a lymph node mass more than 5 cm in greatest dimension

Distant Metastasis (M)

- M0 No distant metastasis
- M1 Distant metastasis
- M1a Nonregional nodal or pulmonary metastasis
- M1b Distant metastasis other than to nonregional lymph nodes and lung

[Continued on next page](#)

Note: All recommendations are category 2A unless otherwise indicated.
Clinical Trials: NCCN believes that the best management of any cancer patient is in a clinical trial. Participation in clinical trials is especially encouraged.

Table 1 (continued)

American Joint Committee on Cancer (AJCC)
TNM Staging System for Testis Cancer (7th ed., 2010)

ANATOMIC STAGE/PROGNOSTIC GROUPS

Group	T	N	M	S (Serum Tumor Markers)
Stage 0	pTis	N0	M0	S0
Stage I	pT1-4	N0	M0	SX
Stage IA	pT1	N0	M0	S0
Stage IB	pT2	N0	M0	S0
	PT3	N0	M0	S0
	PT4	N0	M0	S0
Stage IS	Any pT/TX	N0	M0	S1-3
Stage II	Any pT/Tx	N1-3	M0	SX
Stage IIA	Any pT/TX	N1	M0	S0
	Any pT/TX	N1	M0	S1
Stage IIB	Any pT/TX	N2	M0	S0
	Any pT/TX	N2	M0	S1
Stage IIC	Any pT/TX	N3	M0	S0
	Any pT/TX	N3	M0	S1
Stage III	Any pT/TX	Any N	M1	SX
Stage IIIA	Any pT/TX	Any N	M1a	S0
	Any pT/TX	Any N	M1a	S1
Stage IIIB	Any pT/TX	N1-3	M0	S2
	Any pT/TX	Any N	M1a	S2
Stage IIIC	Any pT/TX	N1-3	M0	S3
	Any pT/TX	Any N	M1a	S3
	Any pT/Tx	Any N	M1b	Any S

Serum Tumor Markers (S)

- SX** Marker studies not available or not performed
- S0** Marker study levels within normal limits
- S1** LDH < 1.5 x N* *and*
hCG (mlu/mL) < 5,000 *and*
AFP (ng/ml) < 1,000
- S2** LDH 1.5-10 x N *or*
hCG (mlu/mL) 5,000-50,000 *or*
AFP (ng/ml) 1,000-10,000
- S3** LDH > 10 x N *or*
hCG (mlu/mL) > 50,000 *or*
AFP (ng/ml) > 10,000

*N indicates the upper limit of normal for the LDH assay.

Used with the permission of the American Joint Committee on Cancer (AJCC), Chicago, Illinois. The original and primary source for this information is the AJCC Cancer Staging Manual, Seventh Edition (2010) published by Springer Science+Business Media, LLC (SBM). (For complete information and data supporting the staging tables, visit www.springer.com.) Any citation or quotation of this material must be credited to the AJCC as its primary source. The inclusion of this information herein does not authorize any reuse or further distribution without the expressed, written permission of Springer SBM, on behalf of the AJCC.

Note: All recommendations are category 2A unless otherwise indicated.
Clinical Trials: NCCN believes that the best management of any cancer patient is in a clinical trial. Participation in clinical trials is especially encouraged.



Discussion

NCCN Categories of Evidence and Consensus

Category 1: Based upon high-level evidence, there is uniform NCCN consensus that the intervention is appropriate.

Category 2A: Based upon lower-level evidence, there is uniform NCCN consensus that the intervention is appropriate.

Category 2B: Based upon lower-level evidence, there is NCCN consensus that the intervention is appropriate.

Category 3: Based upon any level of evidence, there is major NCCN disagreement that the intervention is appropriate.

All recommendations are category 2A unless otherwise noted.

Table of Contents

Overview.....	2
Literature Search Criteria and Guidelines Update Methodology.....	2
Clinical Presentation.....	3
Diagnosis and Workup and Risk Assessment.....	3
Pure Seminoma.....	4
Pure Seminoma Stages IA and IB.....	4
Pure Seminoma Stage IS.....	7
Pure Seminoma Stages IIA and IIB.....	7
Pure Seminoma Stages IIC and III.....	8

Nonseminoma.....	9
Nonseminoma Stage IA.....	10
Nonseminoma Stage IB.....	10
Nonseminoma Stage IS.....	11
Primary Treatment of Nonseminoma Stage IS.....	11
Nonseminoma Stage IIA.....	11
Nonseminoma Stage IIB.....	12
Advanced Metastatic Nonseminoma.....	13
Second-Line Therapy for Metastatic Germ Cell Tumors.....	14
References.....	16

Overview

An estimated 8,430 new cases of testicular cancer will be diagnosed in the United States in 2015.¹ Germ cell tumors (GCTs) comprise 95% of malignant tumors arising in the testes. These tumors also occur occasionally in extragonadal primary sites, but they are still managed the same as testicular GCTs. GCTs are relatively uncommon tumors and account for 1% of all male tumors.¹ Testicular GCTs constitute the most common solid tumor in men between the ages of 20 and 34 years,² and the incidence of testicular GCTs has been increasing in the past two decades.³⁻⁶

Several risk factors for GCT development have been identified, including prior history of a GCT, positive family history, cryptorchidism, testicular dysgenesis, and Klinefelter's syndrome.⁷⁻⁹

GCTs are classified as seminoma or nonseminoma. Nonseminomatous tumors often include multiple cell types, including embryonal cell carcinoma, choriocarcinoma, yolk sac tumor, and teratoma. Teratomas are considered to be either mature or immature depending on whether adult-type differential cell types or partial somatic differentiation, similar to that present in the fetus, is found. Rarely, a teratoma histologically resembles a somatic cancer, such as sarcoma or adenocarcinoma, and is then referred to as a teratoma with malignant transformation.

The serum tumor markers alpha-fetoprotein (AFP), lactate dehydrogenase (LDH), and beta-human chorionic gonadotropin (beta-hCG) are critical in diagnosing the GCTs, determining prognosis, and assessing treatment outcome.

Serum tumor markers should be determined before and after treatment and throughout the follow-up period. Serum tumor markers are very useful for monitoring all stages of nonseminomas. Serum markers are

also useful in monitoring metastatic seminomas, because elevated marker levels are the early signs of relapse.

LDH is a less specific marker compared to AFP and hCG. AFP is a serum tumor marker produced by nonseminomatous cells (ie, embryonal carcinoma, yolk-sac tumor) and may be seen at any stage. The approximate half-life of AFP is 5 to 7 days. A nonseminoma, therefore, is associated with elevated serum concentrations of AFP. When patients with a histologically "pure" testicular seminoma have an elevated level of AFP, it is generally assumed that an undetected focus of nonseminoma is present.^{10,11} An elevated serum concentration of beta-hCG, which has a half-life of approximately 1 to 3 days, may also be present with seminomatous and nonseminomatous tumors. The elevations of beta-hCG need to be interpreted with caution as hypogonadism and marijuana use may cause benign serum elevations of beta-HCG.

Nonseminoma is the more clinically aggressive tumor. When both seminoma and elements of a nonseminoma are present, management follows that for a nonseminoma. Therefore, the diagnosis of a seminoma is restricted to pure seminoma histology and a normal serum concentration of AFP.

The 5-year survival for testis cancer is 98%.² A delay in diagnosis correlates with a higher stage at presentation. Standard therapy has been established at essentially all stages of management and must be closely followed to ensure the potential for cure.

Literature Search Criteria and Guidelines Update Methodology

Prior to the update of this version of the NCCN Guidelines for Testicular Cancer, an electronic search of the PubMed database was performed

to obtain key literature in Testicular Cancer published between 07/28/13 and 07/28/14, using the following search terms: Testicular Cancer. An update search was carried out before the publication of this document. The PubMed database was chosen as it remains the most widely used resource for medical literature and indexes only peer-reviewed biomedical literature.¹²

The search results were narrowed by selecting studies in humans published in English. Results were confined to the following article types: Clinical Trial, Phase II; Clinical Trial, Phase III; Clinical Trial, Phase IV; Guideline; Randomized Controlled Trial; Meta-Analysis; Systematic Reviews; and Validation Studies.

The PubMed search resulted in 277 citations and their potential relevance was examined. The data from key PubMed articles as well as articles from additional sources deemed as relevant to these Guidelines and/or discussed by the panel have been included in this version of the Discussion section (eg, e-publications ahead of print, meeting abstracts). Any recommendations for which high-level evidence is lacking are based on the panel's review of lower-level evidence and expert opinion.

The complete details of the development and update of the NCCN Guidelines are available on the [NCCN webpage](#).

Clinical Presentation

A painless solid testicular mass is pathognomonic for testicular tumor. More often, patients present with testicular discomfort or swelling suggestive of epididymitis or orchitis. A trial of antibiotics may be given in this circumstance, but persistent tenderness, swelling, or any palpable abnormality warrants further evaluation.

Diagnosis and Workup and Risk Assessment

Imaging and Blood Tests

If an intratesticular mass is identified, complete blood count, creatinine, electrolytes, and liver enzymes should be obtained.

Testicular ultrasound serves to confirm the presence of a testicular mass and to explore the contralateral testis. It is sensitive and has an important role in determining whether a mass is intra- or extratesticular.¹³

Further evaluation includes measurement of the serum tumor markers, and a chest x-ray. Serum tumor markers are critical in the assignment of prognosis and management during treatment as well. Serum tumor markers are prognostic factors and contribute to diagnosis and staging.¹⁴ Markers are assessed before orchiectomy and repeated after orchiectomy. Elevated values of beta-hCG, LDH, or AFP should be followed up with repeated tests to allow precise staging.

Biopsy may also be considered if a suspicious intratesticular abnormality, such as a hypoechoic mass or macrocalcification, is identified on ultrasound. In contrast, if microcalcifications without any other abnormality can be observed, testicular biopsy is not necessary.

In patients of reproductive age, sperm banking must be discussed.^{15,16} It must be discussed with the patients before undergoing any therapeutic intervention that may compromise fertility, including surgery, radiation therapy, and chemotherapy.¹⁷⁻¹⁹ If sperm banking is desired, it may be performed either before or after orchiectomy but certainly prior to subsequent therapy.

Primary Treatment

Inguinal orchiectomy is considered the primary treatment for most patients who present with a suspicious testicular mass.²⁰ An open inguinal biopsy of the contralateral testis is not routinely performed, but can be considered when a cryptorchid testis or marked atrophy is present.²¹ The extent of primary tumor is classified after orchiectomy, and therefore pathologic (p) stage is assigned to the primary tumor (T).

Further management is dictated by histology, a diagnosis of pure seminoma or nonseminoma (includes mixed seminoma tumors and seminoma histology with elevated AFP), and stage. Though rare, when a patient presents with rapidly increasing beta-hCG, symptoms related to disseminated disease and a testicular mass, chemotherapy can be initiated immediately without waiting for a biopsy diagnosis.

Staging

The TNM staging is based on post-orchiectomy value of beta-HCG, LDH, and AFP values. To assess for metastatic disease, it is important to obtain the half-life kinetics of serum tumor markers after orchiectomy; determine the status of retroperitoneal lymph nodes; determine the presence of lung metastasis; and determine the presence of brain or bone metastasis if suspicious clinical symptoms are present.

Risk Classification for Advanced Disease

In 1997, the International Germ Cell Cancer Consensus Group (IGCCCG) defined a prognostic factor-based classification system based on identification of some clinically independent prognostic features such as extent of disease and levels of serum tumor markers post-orchiectomy. Post-orchiectomy markers are utilized to classify the patient according to the IGCCCG risk classification. This classification

categorizes patients with pure seminoma and non-seminoma GCT into good-, intermediate-, or poor-risk groups.²²

Definition of stage and risk classification is done according to the American Joint Committee on Cancer (AJCC) and IGCCCG classification.

Pure Seminoma

If a GCT is found, an abdominopelvic CT scan is performed. Abdominopelvic CT scanning is used to assess the retroperitoneal nodes.²³

A chest CT is indicated if the abdominopelvic CT shows retroperitoneal adenopathy or the chest x-ray shows abnormal results. A chest CT scan is a sensitive way to evaluate the thorax and mediastinal nodes.²⁴

The NCCN Panel Members recommend a brain MRI or bone scan, only if there is suspicion of metastases to these organs.

Elevated values of beta-HCG, LDH, or AFP should be followed with repeated tests. Serum concentrations of beta-hCG and LDH may be elevated in patients with seminoma. An elevated AFP level indicates nonseminoma, and the patient should be managed accordingly. Initial management of pure seminoma involves a radical inguinal orchiectomy. Orchiectomy is both diagnostic and therapeutic. Patients with seminoma arising from an extragonadal site, such as the mediastinum, are treated with standard chemotherapy regimens according to risk status.

Pure Seminoma Stages IA and IB

Primary Treatment for Pure Seminoma Stages IA and IB

Most patients with stage I seminoma are cured by orchiectomy alone. A small percentage of patients relapse. To prevent relapse in patients

with stages IA and IB pure seminoma, the standard management options after initial orchiectomy include active surveillance, radiotherapy, or chemotherapy with 1 or 2 cycles of carboplatin. The disease-specific survival for stage I disease is 99% irrespective of the management strategy used.²⁵

Surveillance: A number of prospective non-randomized studies of surveillance have been conducted.²⁶⁻²⁹ The relapse rate seen in these studies is 15% to 20% at 5 years, and most of the relapses are first detected in infra-diaphragmatic lymph nodes.²⁷⁻²⁹ Some studies report tumor size greater than 4 cm and rete testis invasion as a risk factor in predicting relapse in patients.^{28,30,31} A validation study by Chung et al revealed that tumor size >4 cm and rete testis invasion were not predictors of relapse.^{32,33} Therefore, the NCCN Panel Members discourage risk-adapted management using tumor size >4 cm and rete testis invasion for stage I pure seminoma. A retrospective study analyzed a total of 2,483 patients with clinical stage I GCT managed with active surveillance. The analyses showed that 173 of 1,344 (13%) patients with stage 1 seminoma relapsed. Median time to relapse was 14 months (range, 2–84 months). Ninety two percent of the recurrences were observed within 3 years. The overall five-year disease-specific survival was 99.0%.^{34,35} Surveillance is listed as the *preferred* option (category 1) for patients with pT1-pT3 tumors by the NCCN Testicular Cancer Panel.

If surveillance is not applicable, alternatives are either adjuvant carboplatin or adjuvant radiotherapy as described below. Each approach has distinct advantages and disadvantages. The physicians should discuss these with the patients and their families and pick the best approach on a case-by-case basis.

Adjuvant Therapy: Oliver et al reported on the results of a trial that randomized 1477 patients with stage 1 testicular cancer to undergo either radiotherapy or one injection of carboplatin.³⁶ In the study, carboplatin (area under the curve [AUC] X 7) was administered intravenously. The dose was calculated by the formula 7 X (glomerular filtration rate [GFR, mL/min] + 25 mg). With a median follow-up of 4 years, the relapse-free survival rates for both groups were similar.³⁶ Late relapses and secondary GCTs can occur beyond 5 and 10 years. Therefore, the investigators continued to follow these patients. The updated results reported non-inferiority of single-dose carboplatin versus radiation therapy.³⁷ In an intent-to-treat analysis, the relapse-free rates at 5 years were 94.7% for the carboplatin arm and 96% for the radiotherapy arm (hazard ratio, 1.25; *P* = 0.37). There were 2 cases of contralateral GCTs on carboplatin versus 15 on radiation therapy with a hazard ratio of 0.22; the contralateral GCT-free rates at 5 years were 99.8% and 98.8%, respectively. The authors concluded that a single dose of carboplatin is less toxic and as effective in preventing disease recurrence as adjuvant radiotherapy in men with stage I pure seminoma after orchiectomy.³⁷ Two courses of adjuvant carboplatin have also been reported to reduce the relapse rate.³⁸

The NCCN Panel does not prefer the routine use of adjuvant therapy for stage I seminoma patients as the risk of recurrence is low compared to the potential harms of adjuvant therapy. It has been suggested that radiotherapy might increase the risk of a subsequent cardiac event,³⁹ but recent other analyses have not confirmed this risk.⁴⁰

Another study found that moderate-dose infradiaphragmatic RT for stage I seminoma was associated with increased risks of second cancers (non-testicular germ cell) to organs in the radiation field. As with RT, platinum-based chemotherapy has been associated with an increased risk of cancer and heart disease.

However, if adjuvant chemotherapy is opted, the NCCN Testicular Cancer Panel recommends carboplatin AUC X 7 for either 1 or 2 cycles as a category 2A recommendation for patients with stages IA and IB pure seminoma.

If RT is delivered, the NCCN Panel recommends a total dose of 20.0 Gy (midplane) in 10 daily 2.0 Gy fractions,⁴¹ given to an infradiaphragmatic area, including para-aortic lymph nodes; in special circumstances, it may include the ipsilateral ilioinguinal nodes.⁴²⁻⁴⁵ Patients for whom RT is generally not given include those at higher risk for morbidity from radiation therapy such as those with a history of pelvic surgery. Prophylaxis to the mediastinum is not provided, because relapse rarely occurs at this site.

For patients with stages IA and IB pure seminoma, adjuvant radiation therapy to include para-aortic nodes is also a category 2A recommendation in the NCCN Guidelines for Testicular Cancer, though active surveillance is preferred (see *Principles of Radiotherapy for Pure Testicular Seminoma* in the algorithm).

Follow-up After Primary Treatment for Pure Seminoma Stages IA and IB

For follow-up, it is important to distinguish the different risk of recurrence associated with each treatment modality (surveillance vs. adjuvant therapy). An analysis of more than 5,000 stage I seminoma patients from various trials showed that independent of the treatment modality, the risk of recurrence is highest in the first 2 years and decreases after that.⁴⁶ The NCCN Panel recommends performing testicular ultrasound in case other recommended tests are equivocal.

Follow-up During Active Surveillance: The NCCN Panel has provided updated guidelines for follow-up of patients with stage 1 seminoma on

active surveillance (see TEST-A, page 1 of 2). Follow-up for patients on surveillance includes a history and physical, with measurement of post-orchietomy serum tumor markers (AFP, beta-HCG, and LDH), performed every 3 to 6 months for the first year, every 6 to 12 months for years 2 to 3, and annually thereafter.⁴⁷⁻⁴⁹

There is controversy regarding how many imaging studies must be performed in patients on active surveillance. The NCCN Panel recommends abdominal/pelvic CT every 3, 6, and 12 months for the first year, every 6 to 12 months for years 2 and 3, and then every 12 to 24 months for years 4 and 5.

No initial relapses in the lung have been reported in studies of patients with stage I seminoma managed by active surveillance; therefore, according to the NCCN Panel routine chest imaging during surveillance is only indicated for patients with thoracic symptoms.

A clinical trial in the United Kingdom, entitled TRISST (MRC TE24/TRial of Imaging and Schedule in Seminoma Testis), is currently studying whether a reduced CT schedule or MRI could be used as a safe and effective alternative to standard CT-based surveillance in the management of stage I seminoma.⁵⁰

Follow-up After Adjuvant Treatment (carboplatin or RT): The risk of recurrence 5 years after adjuvant treatment is <0.3% annually.⁴⁶ Follow-up of patients treated with adjuvant therapy (carboplatin or RT) includes a history and physical, with measurement of post-orchietomy serum tumor markers (AFP, beta-HCG, and LDH) performed every 6 to 12 months for the first 2 years and annually thereafter.

Patients treated with para-aortic radiation therapy have a slightly higher rate of *pelvic* relapse compared with those treated with “dog-leg” RT.^{43,46,51,52}

In a meta-analysis of 2,466 patients, Mead et al reported that recurrence rarely occurred after more than 3 years from treatment with either RT or carboplatin.²⁵ Relapse occurred after 3 years only in 4 out of the 2,466 patients (0.2%).²⁵ Since the rate of recurrence for patients treated with chemotherapy and radiation therapy beyond 3 years is very low, the NCCN Panel recommends performing abdominal and pelvic CT scans annually for 3 years in patients treated with radiotherapy or carboplatin. Chest x-rays should be obtained only when clinically indicated. Recurrences are treated according to the stage at relapse.²⁵

Pure Seminoma Stage IS

Primary Treatment for Pure Seminoma Stage IS

By the AJCC definition, stage IS requires persistent elevation of serum tumor markers (LDH, AFP, and beta-HCG) following orchiectomy. Stage IS pure seminoma is very uncommon and caution is warranted before intervention based on minimally elevated LDH or beta-HCG, as other causes may be responsible. Persistent elevation of serum markers is usually evidence of metastatic disease, which will show up radiographically if doubt exists in the diagnosis.

Follow-up After Primary Radiation Treatment for Pure Seminoma Stage IS

The NCCN Panel recommends repeating evaluation of serum markers and performing imaging studies to determine the extent of disease. If there is persistent elevation of markers, treatment with chemotherapy is similar to that of nonseminoma (see section on non-seminoma below).

Pure Seminoma Stages IIA and IIB

Primary Treatment for Pure Seminoma Stages IIA

Stage IIA is defined as metastatic disease to lymph nodes, with a lymph node mass measuring less than or equal to 2 cm in diameter in greatest dimension on CT scan, and stage IIB as disease measuring greater than 2 but less than 5 cm in maximum diameter.

RT has been the mainstay of treatment in stage IIA and IIB seminoma patients with low-volume disease.⁵³⁻⁵⁵ The NCCN Panel prefers RT over chemotherapy for patients with stage IIA. The relapse rates are moderate (5%–6% for stage IIA), and overall survival is almost 100%.^{53,55,56} The standard radiation field compared with stage I is extended from the para-aortic region to include an ipsilateral iliac field in two consecutive anteroposterior-posteroanterior phases without a break in between. The initial phase consists of radiation to modified dog-leg fields consisting of a dose of 20.0 Gy (midplane) in 10 daily 2.0 Gy fractions⁴² or 25.5 Gy in 15 daily 1.7 Gy fractions.⁵⁷ The panel prefers modified dog-leg fields as described by Classen et al.⁵³ For details on field arrangement, see *Principles of Radiotherapy for Pure Testicular Seminoma* in the algorithm.

The second phase (cone down) of radiotherapy consists of daily 2.0 Gy fractions to a cumulative total dose of approximately 30 Gy for stage IIA and 36 Gy for selected patients with non-bulky stage IIB disease.⁵³ As with the management of stage I disease, prophylactic mediastinal radiation therapy is not indicated for stage II disease.⁵⁸

For stage IIB seminoma patients such as those with adenopathy measuring more than 3 cm,⁵⁹ chemotherapy with 4 courses of etoposide and cisplatin (EP) or 3 cycles of bleomycin, etoposide, and cisplatin (BEP) is the preferred alternative to radiotherapy.^{56,60} For

patients with stage IIA disease, chemotherapy with 4 cycles of EP or 3 cycles of BEP is an option for patients with multiple positive nodes.

Follow-up for Stages IIA and non-bulky IIB Pure Seminoma After Primary Treatment

The recommended follow-up schedules after radiation therapy for patients with stage IIA and non-bulky IIB tumors include a history and physical with measurement of post-orchietomy serum tumor markers (AFP, beta-HCG, and LDH), performed every 3 months for year 1 and then every 6 months for years 2 through 5.

Chest x-ray is recommended every 6 months for the first 2 years. An abdominal CT scan is recommended at 3 months, then at 6 and 12 months in year 1, and then annually for years 2 and 3 after radiotherapy and as clinically indicated thereafter.

The follow-up of stage II patients with bulky tumors treated with chemotherapy is similar to follow-up after chemotherapy for patients with stages II and III and is discussed in the section below on *Follow-up of Pure Seminoma Bulky Stage II and Stage III After Chemotherapy*.

Pure Seminoma Stages IIC and III

Primary Treatment for Pure Seminoma Stages IIC and III

Patients with stage IIC or III disease are those considered at either good or intermediate risk. All stage IIC and stage III seminoma is considered good-risk disease except for stage III disease with non-pulmonary visceral metastases (eg, bone, liver, brain), which is considered intermediate risk. Standard chemotherapy is used for both groups of patients. However, for patients with good risk, 3 cycles of BEP⁶¹⁻⁶³ or 4 cycles of EP⁶⁴⁻⁶⁶ are recommended. In contrast, more intensive chemotherapy (ie, 4 cycles of BEP) is recommended for those with intermediate-risk disease.^{67,68} All these chemotherapy options are

category 1 recommendations according to the NCCN Testicular Cancer Panel.

Post-chemotherapy Management of Pure Seminoma Stages IIA, IIB, IIC, and III

After chemotherapy, patients with stage IIA, IIB, IIC, and III are evaluated with serum tumor markers and a CT scan of the chest, abdomen, and pelvis. Patients are then classified according to the presence or absence of a residual mass and the status of serum tumor markers. Patients with normal markers and either no residual mass or residual mass of 3 cm or less need no further treatment. They should undergo surveillance as discussed in the section below, on *Follow-up for Pure Seminoma Bulky Stage II and Stage III After Chemotherapy*.

In cases of residual tumor >3 cm and marker levels that are normal, a PET scan is recommended to assess whether there is residual viable tumor.⁶⁹ A PET scan has a high positive and negative predictive value with regard to the question of remaining disease in patients with residual masses after chemotherapy.⁷⁰ To reduce the incidence of false-positive results, the PET scan is typically performed at least 6 weeks after completion of chemotherapy. Notably, granulomatous disease, such as sarcoid, is a source of false-positive results. The NCCN Panel recommends a PET scan in patients with seminoma, and a residual mass >3 cm and normal levels of markers, approximately 6 weeks after chemotherapy in order to decide whether to continue with surveillance or resume treatment.^{69,71-75}

If the PET scan is negative, no further treatment is needed; however, the patient should undergo follow-up^{76,77} as discussed in the section below, on *Follow-up of Pure Seminoma Bulky Stage II and Stage III After Chemotherapy*.

Since a positive PET scan is a strong indicator of residual active tumor, resection should be considered. Therefore, if technically feasible, retroperitoneal lymph node dissection (RPLND) may be considered (category 2A). The other option, if resection is not feasible, is second-line chemotherapy (category 2A). Cisplatin-based combination chemotherapy is used for second-line treatment.⁷⁸⁻⁸⁰ The regimens are four cycles of TIP (paclitaxel, ifosfamide, cisplatin)⁸¹ or four cycles of VeIP (vinblastine, ifosfamide, cisplatin).^{79,80}

According to the NCCN Guidelines, second-line therapy for seminoma and nonseminoma is similar. It is discussed below in *Second-line Therapy for Metastatic Germ Cell Tumors*. The follow-up of these patients is also described below.

Follow-up of Pure Seminoma Bulky Stage II and Stage III After Chemotherapy The NCCN Panel-recommended follow-up schedules for patients with bulky stage II or stage III disease *after* treatment with chemotherapy *and* either no or ≤ 3 cm residual mass and normal tumor markers includes a history and physical and measurement of post-orchietomy serum tumor markers every 2 months for the first year, every 3 months for the second year, every 6 months for the third and fourth years, and annually for year 5. An abdominal/pelvic CT scan is recommended at 3 and 6 months and then as clinically indicated.⁸² A PET scan may be performed as clinically indicated. Chest x-ray is recommended every 2 months during the first year, every 3 months during the second year, and annually during years 3 through 5. Chest CT is preferred over chest x-ray in patients with thoracic symptoms. Viable tumor cells have been found in tumors >3 cm even with a negative PET scan after chemotherapy treatment.^{83,84} The NCCN Panel notes that patients with PET-negative result and tumor residual

mass measuring >3 cm after chemotherapy should undergo an abdominopelvic CT scan every 6 months for the first year and then annually for 5 years.

Nonseminoma

Similar to the workup for seminoma, if non-seminoma is found, CT of the abdomen and pelvis should be performed with chest imaging if needed. MRI of the brain and bone scan should be conducted in the case of clinical indicators (symptoms) of involvement. PET scanning does not contribute and routine use is not recommended for nonseminoma patients.^{85,86}

Elevated values of beta-HCG, LDH, or AFP should be followed up with repeated tests. Nonseminoma includes mixed seminoma tumors and seminoma histology with elevated AFP. Post-orchietomy serum markers are important for TNM staging and to classify the patient with nonseminoma according to the IGCCCG risk classification into good-, intermediate-, and poor-risk groups.²²

In patients of reproductive age, sperm banking must be discussed.^{15,16} It must be discussed with the patients before undergoing any therapeutic intervention that may compromise fertility, including surgery, radiation therapy, or chemotherapy.¹⁷⁻¹⁹ If sperm banking is desired, it may be performed either before or after orchietomy, but certainly prior to adjuvant therapy.

Stage-dependent treatment options after inguinal orchietomy include surveillance, chemotherapy, and RPLND. Although the timing of the RPLND may vary, most patients with nonseminoma will undergo an RPLND for either diagnostic or therapeutic purposes at some point during treatment. The major morbidity associated with bilateral

dissection is retrograde ejaculation, resulting in infertility. Nerve dissection techniques preserve antegrade ejaculation in 90% of cases.⁸⁷

Nonseminoma Stage IA

Primary Treatment of Nonseminoma Stage IA

According to the NCCN Testicular Cancer Panel, two management options exist for patients with stage IA disease after orchiectomy: 1) surveillance;⁸⁸⁻⁹² and 2) nerve-sparing RPLND. The cure rate with either approach exceeds 95%. However, the high cure rate associated with surveillance depends on adherence to periodic follow-up examinations and subsequent chemotherapy for the 20% to 30% of patients who experience relapse. Surveillance is the preferred option for patients with stage 1A tumors by the NCCN Panel. Patients who choose surveillance should agree to be compliant for follow-up. When RPLND is performed, it should be done using a nerve-sparing technique.^{93,94} According to the NCCN Guidelines, the nerve-sparing RPLND is recommended within 4 weeks of a CT scan and within 7 to 10 days of repeat serum marker testing to ensure accurate presurgical staging.

Management of Nonseminoma Stage IA After RPLND

After RPLND, if the dissected lymph nodes are not involved with a tumor (pN0), no adjuvant chemotherapy is given. The patients should undergo surveillance. However, if the resected lymph nodes involve tumor, the decision whether to use adjuvant chemotherapy is based on the degree of nodal involvement. Surveillance is preferred over chemotherapy for patients with pN1 disease. Chemotherapy is preferred in patients with pN2 or pN3 disease. Surveillance is an option for patients with pN2 but is not an option for patients with pN3 disease. Recommended chemotherapy regimens include either EP or BEP. Two cycles of either regimen (EP or BEP) are recommended for patients with pN1 or pN2 disease.⁹⁵⁻¹⁰¹ For patients with pN3 disease, longer

courses of chemotherapy with 4 cycles of EP or 3 cycles of BEP is recommended.

Follow-up for Nonseminoma Stage IA

In the updated NCCN Guidelines, the long-term follow-up tests for stage IA patients electing primary surveillance, post-RPLND, or post-chemotherapy include serum marker assessment, chest x-ray, and an abdominal CT scan. The frequency of these tests is outlined in the algorithm on TEST-B page 1 of 3, entitled *Follow-up for Nonseminoma*.

Nonseminoma Stage IB

Primary Treatment of Nonseminoma Stage IB

After orchiectomy, either nerve-sparing RPLND or adjuvant chemotherapy is an option to reduce the risk of relapse in patients with stage IB disease.

Several studies using two cycles of BEP as primary treatment for stage I nonseminoma patients have been reported with relapse-free survival in greater than 95% of patients.^{92,98,102-106} Based on these studies the NCCN Panel considers 1 to 2 cycles of BEP as primary chemotherapy as an option. Late consequences of cisplatin-based chemotherapy have been reported based on long-term follow-up of patients.^{39,107-111} A trial by Albers et al randomized stage I patients after orchiectomy to undergo unilateral RPLND (n = 191) or one adjuvant course of BEP (n = 191).¹¹² After a median follow-up of 4.7 years, two relapses were reported in the group of patients treated with one course of adjuvant BEP and in 13 patients with relapse in the arm treated with RPLND ($P = .0011$). This study indicates that one course of BEP is active in patients and could be an option in patients unable to tolerate the toxicity of treatment. The comparator arm in this trial (unilateral RPLND) is not the standard treatment approach. Therefore, while the results of this

study are promising, this merits further investigation comparing 1 cycle of BEP versus 2 cycles with longer follow-up.

Surveillance alone may be offered to selected patients with T2 disease (category 2B). Vascular invasion is a significant predictor of relapse when orchiectomy is followed by surveillance alone.²⁰ Surveillance is generally not recommended for T2 disease with vascular invasion because of the 50% chance of relapse. Exceptions are made according to individual circumstances. When surveillance is opted in selected patients with T2 disease, both the patient and the physician must be compliant with follow-up recommendations.

Management of Nonseminoma Stage 1B After Primary Treatment

The adjuvant treatment following primary nerve-sparing RPLND for patients with 1B is similar to that described for stage 1A in the section above, on *Management of Nonseminoma Stage 1A After RPLND*.

In the updated NCCN Guidelines, the long-term routine follow-up tests for the select patients with T2 disease undergoing surveillance and for those who underwent chemotherapy include serum marker assessment, chest x-ray, and an abdominal/pelvic CT scan. The frequency of these tests varies depending on the adjuvant management strategy, and the frequency of the tests are outlined in the algorithm on TEST-B page 1 of 3 and 2 of 3, on *Follow-up for Nonseminoma*.

Nonseminoma Stage 1S

Patients with stage 1S disease exhibit a persistent elevation of serum tumor markers post-orchiectomy but no radiographic evidence of disease. The elevated levels of AFP and beta-HCG after orchiectomy must be interpreted with caution, as the reason for marker elevation might be other than disseminated nonseminoma such as hepatobiliary disease, marijuana use, and hypogonadism.

Primary Treatment of Nonseminoma Stage 1S

The consensus recommendation of the NCCN Panel is that these patients be treated with standard chemotherapy with either 4 cycles of EP or 3 cycles of BEP. Both are NCCN category 1 and either regimen is preferable to initial RPLND because these patients nearly always have disseminated disease.^{113,114}

Management of Stage 1S Nonseminoma Post-primary Treatment

The management of patients with stage 1S nonseminoma after primary treatment with chemotherapy is described in *Advanced Metastatic Nonseminoma*, below.

Nonseminoma Stage IIA

Primary Treatment of Nonseminoma Stage IIA

Treatment for patients with stage IIA nonseminoma depends on post-orchiectomy serum tumor marker levels.

For patients with normal post-orchiectomy levels of AFP and HCG, the NCCN Panel considers either primary RPLND (category 2A) or chemotherapy (category 2B) as treatment options for stage IIA.¹¹⁵⁻¹¹⁹ The chemotherapy regimens include 4 cycles of EP or 3 cycles of BEP. Chemotherapy is considered particularly appropriate if the patient has multifocal disease.

For patients with persistently elevated AFP or HCG levels, the NCCN Panel recommends induction chemotherapy. The data supporting this come from 2 retrospective studies of patients with low-stage nonseminoma treated by RPLND.^{120,121} The presence of elevated postorchiectomy AFP or HCG levels was associated with a high risk of relapse.^{120,121}

Management after primary chemotherapy and RPLND is discussed in sections below.

Management After Primary Treatment of Nonseminoma Stage IIA

After primary chemotherapy, the subsequent management depends on marker levels and the residual mass on CT scan. Therefore, the patients must undergo a CT scan before treatment decisions. Lesions less than 1 cm on CT scan may represent false positives and must be interpreted with caution. The options listed by the NCCN Panel for managing stage IIA patients after primary chemotherapy include nerve-sparing bilateral RPLND or surveillance.

The NCCN Testicular Cancer Panel considers nerve-sparing bilateral RPLND a category 2A recommendation for patients with residual mass of 1 cm or greater and category 2B if the residual mass is less than 1 cm. A bilateral RPLND involves removal of lymphatic tissue between both ureters, spanning from the diaphragmatic crus to the bifurcation of the common iliac arteries. The rationale for this extended region of dissection is the greater likelihood of bilateral disease with greater tumor burden.¹²² Referral to high-volume centers must be considered for RPLND post-chemotherapy. Surveillance is an option for selected patients with negative markers or patients with residual mass less than 1 cm.

After primary nerve-sparing RPLND, the treatment options include either surveillance or chemotherapy. The treatment choice depends on the number of positive lymph nodes identified. For example, since RPLND is likely a curative procedure in patients with pathologic stage N0 (pN0), surveillance is the only option listed for this group. Surveillance and chemotherapy are options for patients with pN1 and pN2 disease. RPLND is a curative procedure in 60% to 90% of pN1

patients;^{121,123,124} therefore, the NCCN Panel prefers surveillance over chemotherapy for patients with pN1 disease. The risk of relapse in patients with pN2-pN3 disease is >50%.^{121,123,125} With 2 cycles of adjuvant cisplatin-based chemotherapy, the risk of relapse after RPLND is generally <1%.^{121,126,127} The NCCN Panel prefers 2 cycles of adjuvant chemotherapy for pN2 disease; and full course chemotherapy (not surveillance) is recommended for pN3 disease. Recommended adjuvant chemotherapy regimens for pN1 and pN2 consists of 2 cycles of BEP or 2 cycles of EP,¹²⁸ resulting in a nearly 100% relapse-free survival rate. For pN3, the NCCN Panel recommends a longer chemotherapy course consisting of either 4 cycles of EP or 3 cycles of BEP.

If stage IIA patients have persistent marker elevation (ie, stage IIA, S1), the primary treatment is chemotherapy as described for good-risk nonseminoma in sections below.

Nonseminoma Stage IIB

Primary Treatment of Nonseminoma Stage IIB

Treatment for patients with stage IIB nonseminoma also depends on both post-orchietomy tumor marker levels *and* radiographic findings. When tumor markers are negative, the CT findings determine the proper course of treatment. If abnormal radiographic findings are limited to sites within the lymphatic drainage in the retroperitoneum (ie, the landing zone), two management options are available. One option is to perform nerve-sparing RPLND and to consider adjuvant treatment as described for patients with stage IIA disease. The second option is to treat with primary chemotherapy with either 4 cycles of EP or 3 cycles of BEP, followed by nerve-sparing RPLND or surveillance. Both options of primary chemotherapy or primary RPLND are comparable options in terms of outcome, but side effects and toxicity

are different.¹¹⁶ The reported relapse-free survival with either approach is close to 98%.^{123,128-133}

If metastatic disease (based on radiographic findings) is not confined to the lymphatic drainage (ie, multifocal lymph node metastases outside the lymphatic drainage sites), chemotherapy is recommended with either 4 cycles of EP or 3 cycles of BEP, followed by nerve-sparing RPLND or surveillance.

For stage IIB patients with persistent marker elevation (stage IIB, S1), the primary treatment is chemotherapy as described for good-risk nonseminoma including stages IS, IIC, and IIIA in sections below (see section below). Initial RPLND is not recommended in this situation.

Management After Primary Treatment of Nonseminoma Stage IIB

The management of patients with stage IIB nonseminoma after primary treatment with either nerve-sparing bilateral RPLND or chemotherapy is similar to the management scheme post-primary outlined above for patients with stage IIA nonseminoma.

Advanced Metastatic Nonseminoma

The primary chemotherapy regimens of choice for patients with advanced disease depends on the IGCCCG risk classification.²² This classification categorizes patients as good, intermediate, or poor risk.²² Also, patients with an extragonadal primary site, whether retroperitoneal or mediastinal, are treated with initial chemotherapy.

Primary Treatment of Good-risk Nonseminoma

Based on the IGCCCG good-risk classification, this group includes patients with stages IS, IIA and IIB (with persistent marker elevation), IIC, and IIIA. Treatment for good-risk GCTs were designed to decrease toxicity while maintaining maximal efficacy. Randomized clinical trials

showed that this can be achieved by either substituting etoposide for vinblastine^{134,135} or by eliminating or reducing the dose of bleomycin.^{134,136} Presently two regimens are recommended by the NCCN Testicular Cancer Panel: 4 cycles of EP⁶⁵ or 3 cycles of BEP^{61,63,137,138} (both category 2A). Either regimen is well tolerated and cures approximately 90% of patients with good risk.¹³⁹

Primary Treatment of Intermediate-risk (stage IIB) Nonseminoma

For patients with intermediate risk, the cure rate is approximately 70% with standard therapy using 4 cycles of BEP.^{140,141} For patients with intermediate risk (stage IIB), 4 cycles of BEP is a category 2A recommendation by the NCCN Testicular Cancer Panel.

Primary Treatment of Poor-risk (stage IIIC) Nonseminoma

In patients with poor-risk GCTs (stage IIIC), between 20% and 30% of all patients with metastatic GCTs are not cured with conventional cisplatin therapy and less than one half experience a durable complete response to 4 cycles of BEP; therefore, treatment in a clinical trial is preferred.¹³⁹ The NCCN Panel lists enrolling these patients in clinical trials as their preferred treatment option.

The standard chemotherapy regimen for poor-risk patients is 4 cycles of BEP. The regimen containing VIP (etoposide, ifosfamide, cisplatin) was compared to BEP and found to be more toxic, compared with BEP, but equally effective. Therefore, 4 cycles of VIP may be used for those who may not tolerate bleomycin.¹⁴²

Post-chemotherapy Management for Good-, Intermediate-, and Poor-risk Nonseminoma

At the conclusion of induction chemotherapy, CT scans of the abdomen and pelvis are indicated, along with serum tumor marker assays. PET scans for residual disease have limited predictive value.

If a complete response to chemotherapy is found by radiographic imaging, and the tumor markers are negative, the NCCN Panel lists management options depending on the original stage of the disease: surveillance (category 2B) if original stage was IS; or either surveillance (category 2A) or bilateral RPLND using nerve-sparing technique if possible (category 2B),⁷⁷ if the original stage of disease was IIA, S1, IIB, S1, IIC, or IIIA.

If there is a partial response to chemotherapy or a residual mass is found and the serum tumor markers (AFP and beta-HCG) have normalized, then all sites of residual disease are resected.¹⁴³⁻¹⁴⁵ If only necrotic debris or mature teratoma is encountered, no further therapy is necessary and patients must be put under surveillance. If embryonal, yolk sac, choriocarcinoma, or seminoma elements are found in the residual mass, 2 cycles of conventionally dosed chemotherapy (EP, VeIP, VIP, or TIP) are administered.

The recommended follow-up tests and their frequencies during surveillance, after chemotherapy or after bilateral RPLND, are outlined in the algorithm on page TEST-B 2 of 3, entitled *Follow-up for Nonseminoma*. After patients are rendered disease-free, standard surveillance is initiated.

Patients who experience an incomplete response to first-line therapy are treated with second-line therapy (see section below). The NCCN Testicular Cancer Panel prefers that patients with recurrent nonseminoma be treated at centers with expertise in the management of this disease in conjunction with best supportive care.

Second-Line Therapy for Metastatic Germ Cell Tumors

Patients who do not experience a durable complete response to first-line therapy or those who experience a recurrence can be divided into those with a favorable or unfavorable prognosis based on prognostic factors. Prognostic factors can be used in deciding whether a patient is a candidate for conventional dose therapy or high-dose therapy with stem cell support as a second-line option. To determine the prognosis at initial diagnosis, the IGCCCG classification is used. However, for patients with progressive or relapsed disease after first-line treatment, several prognostic models have been reported.¹⁴⁶⁻¹⁴⁸ Favorable prognostic factors to conventional dose second-line chemotherapy include a testicular primary site, prior complete response to first-line therapy, low levels of post-orchietomy serum tumor markers, and low-volume disease.¹⁴⁶ Standard second-line therapy includes conventional dose chemotherapy or high-dose chemotherapy. The conventional dose regimen includes cisplatin and ifosfamide combined with either vinblastine or paclitaxel.¹⁴⁹

If the patient experiences an incomplete response or relapses after second-line conventional dose chemotherapy, the preferred third-line option, if the second-line therapy included conventional dose chemotherapy, would be high-dose chemotherapy^{150,151} or chemotherapy in the context of a clinical trial. A surgical salvage could be considered if the relapse is in a solitary resectable site.

Unfavorable prognostic features include incomplete response to first-line treatment, high levels of serum markers, high-volume disease, and presence of extratesticular primary tumor. Patients with a testicular primary site and rising post-orchietomy serum tumor markers during first-line therapy are usually considered for high-dose programs. Chemotherapy options for patients with poor prognostic features

include chemotherapy in the context of a clinical trial; conventional-dose second-line therapy (with VeIP or TIP); and high-dose chemotherapy (category 2B). Alternatively, the patients may be put on palliative chemotherapy or salvage surgery if feasible.^{152,153} The high-dose regimens include high-dose carboplatin plus etoposide followed by autologous stem cell transplant^{147,154} or paclitaxel, and ifosfamide followed by high-dose carboplatin plus etoposide with stem cell support.¹⁵⁵

A late relapse (>2 years after completion of primary therapy) occurs in 2% to 3% of survivors.¹⁵⁶⁻¹⁵⁸ The NCCN Panel prefers surgical resection, if technically feasible.^{152,159,160} Conventional dose chemotherapy or high-dose chemotherapy are other options for patients with late relapses.

For patients with unfavorable prognosis and late relapses who do not experience complete response to second-line high-dose therapy, the disease is nearly always incurable; the only exception is the rare patient with elevated serum tumor markers and a solitary site of metastasis (usually retroperitoneal) that undergoes surgical resection.¹⁶¹ Other options are participation in a clinical trial or palliative chemotherapy.

Palliative Therapy

All patients with either persistent or recurrent disease should be considered for palliative chemotherapy or radiation therapy.

The palliative chemotherapy options for patients with intensively pretreated, cisplatin-resistant, or refractory GCT are combinations of gemcitabine with paclitaxel and/or oxaliplatin,¹⁶²⁻¹⁶⁷ or oral etoposide.¹⁶⁸

The recommendation for gemcitabine and oxaliplatin (GEMOX) is based on data from phase II studies.¹⁶²⁻¹⁶⁴ These studies investigated

the efficacy and the toxicity of GEMOX in patients with relapsed or cisplatin-refractory GCTs. The results showed that GEMOX is safe for patients with cisplatin-refractory testicular GCTs and may offer a chance of long-term survival.¹⁶²⁻¹⁶⁴

Gemcitabine and paclitaxel is another option that has shown promising results in a phase II study,¹⁶⁶ and long-term follow-up results with this combination show long-term disease-free survival in the rare patients who progressed after high-dose chemotherapy and had not received prior paclitaxel or gemcitabine.¹⁶⁷

A phase II study of patients with treatment-refractory germ-cell tumors found the combination of gemcitabine, oxaliplatin, and paclitaxel to be effective with acceptable toxicity.¹⁶⁵ In a phase II study in patients who had previous treatment with cisplatin/etoposide combination regimens, high-dose etoposide and carboplatin with autologous bone marrow transplantation showed that single-agent oral etoposide was effective.¹⁶⁸

For palliative therapy, the NCCN Testicular Cancer Panel recommends GEMOX¹⁶²⁻¹⁶⁴; gemcitabine with paclitaxel^{166,167}; gemcitabine with oxaliplatin and paclitaxel¹⁶⁵; or oral etoposide¹⁶⁸ (all are category 2A recommendations).

Treatment of Brain Metastases

The prognosis of patients with brain metastasis is poor.^{169,170} Primary chemotherapy (using a cisplatin-based regimen) is indicated for patients in whom brain metastases are detected and there are data supporting use of radiation therapy with chemotherapy.^{170,171} If clinically indicated and feasible, surgical resection of the metastasis should also be performed.

References

- Siegel RL, Miller KD, Jemal A. Cancer statistics, 2015. *CA Cancer J Clin* 2015;65:5-29. Available at: <http://www.ncbi.nlm.nih.gov/pubmed/25559415>.
- <http://seer.cancer.gov/statfacts/html/testis.html>.
- Huyghe E, Matsuda T, Thonneau P. Increasing incidence of testicular cancer worldwide: a review. *J Urol* 2003;170:5-11. Available at: <http://www.ncbi.nlm.nih.gov/pubmed/12796635>.
- Shanmugalingam T, Soultati A, Chowdhury S, et al. Global incidence and outcome of testicular cancer. *Clin Epidemiol* 2013;5:417-427. Available at: <http://www.ncbi.nlm.nih.gov/pubmed/24204171>.
- Verhoeven RH, Gondos A, Janssen-Heijnen ML, et al. Testicular cancer in Europe and the USA: survival still rising among older patients. *Ann Oncol* 2013;24:508-513. Available at: <http://www.ncbi.nlm.nih.gov/pubmed/23110807>.
- Chia VM, Quraishi SM, Devesa SS, et al. International trends in the incidence of testicular cancer, 1973-2002. *Cancer Epidemiol Biomarkers Prev* 2010;19:1151-1159. Available at: <http://www.ncbi.nlm.nih.gov/pubmed/20447912>.
- Bosl GJ, Motzer RJ. Testicular germ-cell cancer. *N Engl J Med* 1997;337:242-253. Available at: <http://www.ncbi.nlm.nih.gov/pubmed/9227931>.
- Turnbull C, Rahman N. Genome-wide association studies provide new insights into the genetic basis of testicular germ-cell tumour. *Int J Androl* 2011;34:e86-96; discussion e96-87. Available at: <http://www.ncbi.nlm.nih.gov/pubmed/21623831>.
- Greene MH, Kratz CP, Mai PL, et al. Familial testicular germ cell tumors in adults: 2010 summary of genetic risk factors and clinical phenotype. *Endocr Relat Cancer* 2010;17:R109-121. Available at: <http://www.ncbi.nlm.nih.gov/pubmed/20228134>.
- Nazeer T, Ro JY, Amato RJ, et al. Histologically pure seminoma with elevated alpha-fetoprotein: a clinicopathologic study of ten cases. *Oncol Rep* 1998;5:1425-1429. Available at: <http://www.ncbi.nlm.nih.gov/pubmed/9769381>.
- Weissbach L, Bussar-Maatz R, Mann K. The value of tumor markers in testicular seminomas. Results of a prospective multicenter study. *Eur Urol* 1997;32:16-22. Available at: <http://www.ncbi.nlm.nih.gov/pubmed/9266226>.
- U.S. National Library of Medicine-Key MEDLINE® Indicators. Available at: http://www.nlm.nih.gov/bsd/bsd_key.html. Available at:
- Kim W, Rosen MA, Langer JE, et al. US MR imaging correlation in pathologic conditions of the scrotum. *Radiographics* 2007;27:1239-1253. Available at: <http://www.ncbi.nlm.nih.gov/pubmed/17848688>.
- Klein EA. Tumor markers in testis cancer. *Urol Clin North Am* 1993;20:67-73. Available at: <http://www.ncbi.nlm.nih.gov/pubmed/7679533>.
- Ragni G, Somigliana E, Restelli L, et al. Sperm banking and rate of assisted reproduction treatment: insights from a 15-year cryopreservation program for male cancer patients. *Cancer* 2003;97:1624-1629. Available at: <http://www.ncbi.nlm.nih.gov/pubmed/12655518>.
- Saito K, Suzuki K, Iwasaki A, et al. Sperm cryopreservation before cancer chemotherapy helps in the emotional battle against cancer. *Cancer* 2005;104:521-524. Available at: <http://www.ncbi.nlm.nih.gov/pubmed/15968690>.
- Brydoy M, Fossa SD, Klepp O, et al. Paternity following treatment for testicular cancer. *J Natl Cancer Inst* 2005;97:1580-1588. Available at: <http://www.ncbi.nlm.nih.gov/pubmed/16264178>.

18. Huyghe E, Matsuda T, Daudin M, et al. Fertility after testicular cancer treatments: results of a large multicenter study. *Cancer* 2004;100:732-737. Available at: <http://www.ncbi.nlm.nih.gov/pubmed/14770428>.
19. Gordon W, Jr., Siegmund K, Stanisic TH, et al. A study of reproductive function in patients with seminoma treated with radiotherapy and orchidectomy: (SWOG-8711). *Southwest Oncology Group. Int J Radiat Oncol Biol Phys* 1997;38:83-94. Available at: <http://www.ncbi.nlm.nih.gov/pubmed/9212008>.
20. Jones RH, Vasey PA. Part I: testicular cancer--management of early disease. *Lancet Oncol* 2003;4:730-737. Available at: <http://www.ncbi.nlm.nih.gov/pubmed/14662429>.
21. Fossa SD, Chen J, Schonfeld SJ, et al. Risk of contralateral testicular cancer: a population-based study of 29,515 U.S. men. *J Natl Cancer Inst* 2005;97:1056-1066. Available at: <http://www.ncbi.nlm.nih.gov/pubmed/16030303>.
22. International Germ Cell Consensus Classification: a prognostic factor-based staging system for metastatic germ cell cancers. International Germ Cell Cancer Collaborative Group. *J Clin Oncol* 1997;15:594-603. Available at: <http://www.ncbi.nlm.nih.gov/pubmed/9053482>.
23. Leibovitch L, Foster RS, Kopecky KK, Donohue JP. Improved accuracy of computerized tomography based clinical staging in low stage nonseminomatous germ cell cancer using size criteria of retroperitoneal lymph nodes. *J Urol* 1995;154:1759-1763. Available at: <http://www.ncbi.nlm.nih.gov/pubmed/7563341>.
24. See WA, Hoxie L. Chest staging in testis cancer patients: imaging modality selection based upon risk assessment as determined by abdominal computerized tomography scan results. *J Urol* 1993;150:874-878. Available at: <http://www.ncbi.nlm.nih.gov/pubmed/8345604>.
25. Mead GM, Fossa SD, Oliver RT, et al. Randomized Trials in 2466 Patients With Stage I Seminoma: Patterns of Relapse and Follow-up. *J Natl Cancer Inst* 2011;103:241-249. Available at: <http://www.ncbi.nlm.nih.gov/pubmed/21212385>.
26. Groll RJ, Warde P, Jewett MA. A comprehensive systematic review of testicular germ cell tumor surveillance. *Crit Rev Oncol Hematol* 2007;64:182-197. Available at: <http://www.ncbi.nlm.nih.gov/pubmed/17644403>.
27. Aparicio J, Garcia del Muro X, Maroto P, et al. Multicenter study evaluating a dual policy of postorchidectomy surveillance and selective adjuvant single-agent carboplatin for patients with clinical stage I seminoma. *Ann Oncol* 2003;14:867-872. Available at: <http://www.ncbi.nlm.nih.gov/pubmed/12796024>.
28. Warde P, Specht L, Horwich A, et al. Prognostic factors for relapse in stage I seminoma managed by surveillance: a pooled analysis. *J Clin Oncol* 2002;20:4448-4452. Available at: <http://www.ncbi.nlm.nih.gov/pubmed/12431967>.
29. Chung P, Parker C, Panzarella T, et al. Surveillance in stage I testicular seminoma - risk of late relapse. *Can J Urol* 2002;9:1637-1640. Available at: <http://www.ncbi.nlm.nih.gov/pubmed/12431325>.
30. von der Maase H, Specht L, Jacobsen GK, et al. Surveillance following orchidectomy for stage I seminoma of the testis. *Eur J Cancer* 1993;29A:1931-1934. Available at: <http://www.ncbi.nlm.nih.gov/pubmed/8280484>.
31. Warde P, Gospodarowicz MK, Banerjee D, et al. Prognostic factors for relapse in stage I testicular seminoma treated with surveillance. *J Urol* 1997;157:1705-1709; discussion 1709-1710. Available at: <http://www.ncbi.nlm.nih.gov/pubmed/9112510>.
32. Chung PW, Daugaard G, Tyldesley S, et al. Prognostic factors for relapse in stage I seminoma managed with surveillance: A validation

study [abstract]. J Clin Oncol 2010;28:Abstract 4535. Available at: http://meeting.ascopubs.org/cgi/content/abstract/28/15_suppl/4535.

33. Chung P, Warde P. Stage I seminoma: adjuvant treatment is effective but is it necessary? J Natl Cancer Inst 2011;103:194-196. Available at: <http://www.ncbi.nlm.nih.gov/pubmed/21212383>.

34. Kollmannsberger C, Tandstad T, Bedard PL, et al. Patterns of Relapse in Patients With Clinical Stage I Testicular Cancer Managed With Active Surveillance. J Clin Oncol 2014. Available at: <http://www.ncbi.nlm.nih.gov/pubmed/25135991>.

35. Cohn-Cedermark G, Stahl O, Tandstad T, Swenoteca. Surveillance vs. adjuvant therapy of clinical stage I testicular tumors - a review and the SWENOTECA experience. Andrology 2015;3:102-110. Available at: <http://www.ncbi.nlm.nih.gov/pubmed/25270123>.

36. Oliver RT, Mason MD, Mead GM, et al. Radiotherapy versus single-dose carboplatin in adjuvant treatment of stage I seminoma: a randomised trial. Lancet 2005;366:293-300. Available at: <http://www.ncbi.nlm.nih.gov/pubmed/16039331>.

37. Oliver RT, Mead GM, Rustin GJ, et al. Randomized trial of carboplatin versus radiotherapy for stage I seminoma: Mature results on relapse and contralateral testis cancer rates in MRC TE19/EORTC 30982 study (ISRCTN27163214). J Clin Oncol 2011. Available at: <http://www.ncbi.nlm.nih.gov/pubmed/21282539>.

38. Aparicio J, Germa JR, Garcia del Muro X, et al. Risk-adapted management for patients with clinical stage I seminoma: the Second Spanish Germ Cell Cancer Cooperative Group study. J Clin Oncol 2005;23:8717-8723. Available at: <http://www.ncbi.nlm.nih.gov/pubmed/16260698>.

39. Huddart RA, Norman A, Shahidi M, et al. Cardiovascular disease as a long-term complication of treatment for testicular cancer. J Clin Oncol 2003;21:1513-1523. Available at: <http://www.ncbi.nlm.nih.gov/pubmed/12697875>.

40. Beard CJ, Travis LB, Chen MH, et al. Outcomes in stage I testicular seminoma: a population-based study of 9193 patients. Cancer 2013;119:2771-2777. Available at: <http://www.ncbi.nlm.nih.gov/pubmed/23633409>.

41. Garmezay B, Pagliaro LC. Choosing treatment for stage I seminoma: who should get what? Oncology (Williston Park) 2009;23:753, 759. Available at: <http://www.ncbi.nlm.nih.gov/pubmed/19777759>.

42. Jones WG, Fossa SD, Mead GM, et al. Randomized trial of 30 versus 20 Gy in the adjuvant treatment of stage I Testicular Seminoma: a report on Medical Research Council Trial TE18, European Organisation for the Research and Treatment of Cancer Trial 30942 (ISRCTN18525328). J Clin Oncol 2005;23:1200-1208. Available at: <http://www.ncbi.nlm.nih.gov/pubmed/15718317>.

43. Fossa SD, Horwich A, Russell JM, et al. Optimal planning target volume for stage I testicular seminoma: A Medical Research Council randomized trial. Medical Research Council Testicular Tumor Working Group. J Clin Oncol 1999;17:1146. Available at: <http://www.ncbi.nlm.nih.gov/pubmed/10561173>.

44. Dinniwell R, Chan P, Czarnota G, et al. Pelvic lymph node topography for radiotherapy treatment planning from ferumoxtran-10 contrast-enhanced magnetic resonance imaging. Int J Radiat Oncol Biol Phys 2009;74:844-851. Available at: <http://www.ncbi.nlm.nih.gov/pubmed/19095369>.

45. McMahon CJ, Rofsky NM, Pedrosa I. Lymphatic metastases from pelvic tumors: anatomic classification, characterization, and staging. Radiology 2010;254:31-46. Available at: <http://www.ncbi.nlm.nih.gov/pubmed/20032141>.

46. Martin JM, Panzarella T, Zwahlen DR, et al. Evidence-based guidelines for following stage 1 seminoma. Cancer 2007;109:2248-2256. Available at: <http://www.ncbi.nlm.nih.gov/pubmed/17437287>.

47. Souchon R, Hartmann M, Krege S, et al. Interdisciplinary evidence-based recommendations for the follow-up of early stage seminomatous testicular germ cell cancer patients. *Strahlenther Onkol* 2011;187:158-166. Available at: <http://www.ncbi.nlm.nih.gov/pubmed/21347634>.
48. Aparicio J, Maroto P, del Muro XG, et al. Risk-adapted treatment in clinical stage I testicular seminoma: the third Spanish Germ Cell Cancer Group study. *J Clin Oncol* 2011;29:4677-4681. Available at: <http://www.ncbi.nlm.nih.gov/pubmed/22042940>.
49. Daugaard G, Petersen PM, Rorth M. Surveillance in stage I testicular cancer. *APMIS* 2003;111:76-83; discussion 83-75. Available at: <http://www.ncbi.nlm.nih.gov/pubmed/12752240>.
50. TRISST (MRC TE24) Trial of imaging and schedule in seminoma testis. Available at: http://www.ctu.mrc.ac.uk/our_research/research_areas/cancer/studies/trisst_mrc_te24/.
51. Livsey JE, Taylor B, Mobarek N, et al. Patterns of relapse following radiotherapy for stage I seminoma of the testis: implications for follow-up. *Clin Oncol (R Coll Radiol)* 2001;13:296-300. Available at: <http://www.ncbi.nlm.nih.gov/pubmed/11554630>.
52. van As NJ, Gilbert DC, Money-Kyrle J, et al. Evidence-based pragmatic guidelines for the follow-up of testicular cancer: optimising the detection of relapse. *Br J Cancer* 2008;98:1894-1902. Available at: <http://www.ncbi.nlm.nih.gov/pubmed/18542063>.
53. Classen J, Schmidberger H, Meisner C, et al. Radiotherapy for stages IIA/B testicular seminoma: final report of a prospective multicenter clinical trial. *J Clin Oncol* 2003;21:1101-1106. Available at: <http://www.ncbi.nlm.nih.gov/pubmed/12637477>.
54. Patterson H, Norman AR, Mitra SS, et al. Combination carboplatin and radiotherapy in the management of stage II testicular seminoma: comparison with radiotherapy treatment alone. *Radiother Oncol* 2001;59:5-11. Available at: <http://www.ncbi.nlm.nih.gov/pubmed/11295200>.
55. Schmidberger H, Bamberg M, Meisner C, et al. Radiotherapy in stage IIA and IIB testicular seminoma with reduced portals: a prospective multicenter study. *Int J Radiat Oncol Biol Phys* 1997;39:321-326. Available at: <http://www.ncbi.nlm.nih.gov/pubmed/9308934>.
56. Detti B, Livi L, Scoccianti S, et al. Management of Stage II testicular seminoma over a period of 40 years. *Urol Oncol* 2009;27:534-538. Available at: <http://www.ncbi.nlm.nih.gov/pubmed/18848787>.
57. Choo R, Sandler H, Warde P, et al. Survey of radiation oncologists: practice patterns of the management of stage I seminoma of testis in Canada and a selected group in the United States. *Can J Urol* 2002;9:1479-1485. Available at: <http://www.ncbi.nlm.nih.gov/pubmed/12010592>.
58. Gospodarwicz MK, Sturgeon JF, Jewett MA. Early stage and advanced seminoma: role of radiation therapy, surgery, and chemotherapy. *Semin Oncol* 1998;25:160-173. Available at: <http://www.ncbi.nlm.nih.gov/pubmed/9562449>.
59. Domont J, Massard C, Patrikidou A, et al. A risk-adapted strategy of radiotherapy or cisplatin-based chemotherapy in stage II seminoma. *Urol Oncol* 2011. Available at: <http://www.ncbi.nlm.nih.gov/pubmed/21665493>.
60. Garcia-del-Muro X, Maroto P, Guma J, et al. Chemotherapy as an alternative to radiotherapy in the treatment of stage IIA and IIB testicular seminoma: a Spanish Germ Cell Cancer Group Study. *J Clin Oncol* 2008;26:5416-5421. Available at: <http://www.ncbi.nlm.nih.gov/pubmed/18936476>.
61. de Wit R, Roberts JT, Wilkinson PM, et al. Equivalence of three or four cycles of bleomycin, etoposide, and cisplatin chemotherapy and

of a 3- or 5-day schedule in good-prognosis germ cell cancer: a randomized study of the European Organization for Research and Treatment of Cancer Genitourinary Tract Cancer Cooperative Group and the Medical Research Council. *J Clin Oncol* 2001;19:1629-1640. Available at: <http://www.ncbi.nlm.nih.gov/pubmed/11250991>.

62. Loehrer PJ, Sr., Johnson D, Elson P, et al. Importance of bleomycin in favorable-prognosis disseminated germ cell tumors: an Eastern Cooperative Oncology Group trial. *J Clin Oncol* 1995;13:470-476. Available at: <http://www.ncbi.nlm.nih.gov/pubmed/7531223>.

63. Saxman SB, Finch D, Gonin R, Einhorn LH. Long-term follow-up of a phase III study of three versus four cycles of bleomycin, etoposide, and cisplatin in favorable-prognosis germ-cell tumors: the Indian University experience. *J Clin Oncol* 1998;16:702-706. Available at: <http://www.ncbi.nlm.nih.gov/pubmed/9469360>.

64. Bajorin DF, Sarosdy MF, Pfister DG, et al. Randomized trial of etoposide and cisplatin versus etoposide and carboplatin in patients with good-risk germ cell tumors: a multiinstitutional study. *J Clin Oncol* 1993;11:598-606. Available at: <http://www.ncbi.nlm.nih.gov/pubmed/8386751>.

65. Xiao H, Mazumdar M, Bajorin DF, et al. Long-term follow-up of patients with good-risk germ cell tumors treated with etoposide and cisplatin. *J Clin Oncol* 1997;15:2553-2558. Available at: <http://www.ncbi.nlm.nih.gov/pubmed/9215824>.

66. Kondagunta GV, Bacik J, Bajorin D, et al. Etoposide and cisplatin chemotherapy for metastatic good-risk germ cell tumors. *J Clin Oncol* 2005;23:9290-9294. Available at: <http://www.ncbi.nlm.nih.gov/pubmed/16361627>.

67. Tjan-Heijnen VC, Oosterhof GO, de Wit R, De Mulder PH. Treatment in germ cell tumours: state of the art. *Eur J Surg Oncol* 1997;23:110-117. Available at: <http://www.ncbi.nlm.nih.gov/pubmed/9158183>.

68. de Wit R, Louwerens M, de Mulder PH, et al. Management of intermediate-prognosis germ-cell cancer: results of a phase I/II study of Taxol-BEP. *Int J Cancer* 1999;83:831-833. Available at: <http://www.ncbi.nlm.nih.gov/pubmed/10597204>.

69. Becherer A, De Santis M, Karanikas G, et al. FDG PET is superior to CT in the prediction of viable tumour in post-chemotherapy seminoma residuals. *Eur J Radiol* 2005;54:284-288. Available at: <http://www.ncbi.nlm.nih.gov/pubmed/15837411>.

70. Hinz S, Schrader M, Kempkensteffen C, et al. The role of positron emission tomography in the evaluation of residual masses after chemotherapy for advanced stage seminoma. *J Urol* 2008;179:936-940; discussion 940. Available at: <http://www.ncbi.nlm.nih.gov/pubmed/18207171>.

71. Cremerius U, Wildberger JE, Borchers H, et al. Does positron emission tomography using 18-fluoro-2-deoxyglucose improve clinical staging of testicular cancer?--Results of a study in 50 patients. *Urology* 1999;54:900-904. Available at: <http://www.ncbi.nlm.nih.gov/pubmed/10565755>.

72. Albers P, Bender H, Yilmaz H, et al. Positron emission tomography in the clinical staging of patients with Stage I and II testicular germ cell tumors. *Urology* 1999;53:808-811. Available at: <http://www.ncbi.nlm.nih.gov/pubmed/10197862>.

73. Spermon JR, De Geus-Oei LF, Kiemeny LA, et al. The role of (18)fluoro-2-deoxyglucose positron emission tomography in initial staging and re-staging after chemotherapy for testicular germ cell tumours. *BJU Int* 2002;89:549-556. Available at: <http://www.ncbi.nlm.nih.gov/pubmed/11942962>.

74. De Santis M, Pont J. The role of positron emission tomography in germ cell cancer. *World J Urol* 2004;22:41-46. Available at: <http://www.ncbi.nlm.nih.gov/pubmed/15024601>.

75. De Santis M, Becherer A, Bokemeyer C, et al. 2-18fluoro-deoxy-D-glucose positron emission tomography is a reliable predictor for viable tumor in postchemotherapy seminoma: an update of the prospective multicentric SEMPET trial. *J Clin Oncol* 2004;22:1034-1039. Available at: <http://www.ncbi.nlm.nih.gov/pubmed/15020605>.

76. Ehrlich Y, Brames MJ, Beck SD, et al. Long-term follow-up of Cisplatin combination chemotherapy in patients with disseminated nonseminomatous germ cell tumors: is a postchemotherapy retroperitoneal lymph node dissection needed after complete remission? *J Clin Oncol* 2010;28:531-536. Available at: <http://www.ncbi.nlm.nih.gov/pubmed/20026808>.

77. Kollmannsberger C, Daneshmand S, So A, et al. Management of disseminated nonseminomatous germ cell tumors with risk-based chemotherapy followed by response-guided postchemotherapy surgery. *J Clin Oncol* 2010;28:537-542. Available at: <http://www.ncbi.nlm.nih.gov/pubmed/20026807>.

78. Kondagunta GV, Bacik J, Sheinfeld J, et al. Paclitaxel plus ifosfamide followed by high-dose carboplatin plus etoposide in previously treated germ cell tumors. *J Clin Oncol* 2007;25:85-90. Available at: <http://www.ncbi.nlm.nih.gov/pubmed/17194908>.

79. Miller KD, Loehrer PJ, Gonin R, Einhorn LH. Salvage chemotherapy with vinblastine, ifosfamide, and cisplatin in recurrent seminoma. *J Clin Oncol* 1997;15:1427-1431. Available at: <http://www.ncbi.nlm.nih.gov/pubmed/9193335>.

80. Loehrer PJ, Sr., Lauer R, Roth BJ, et al. Salvage therapy in recurrent germ cell cancer: ifosfamide and cisplatin plus either vinblastine or etoposide. *Ann Intern Med* 1988;109:540-546. Available at: <http://www.ncbi.nlm.nih.gov/pubmed/2844110>.

81. Kondagunta GV, Bacik J, Donadio A, et al. Combination of paclitaxel, ifosfamide, and cisplatin is an effective second-line therapy for patients with relapsed testicular germ cell tumors. *J Clin Oncol*

2005;23:6549-6555. Available at: <http://www.ncbi.nlm.nih.gov/pubmed/16170162>.

82. Schmoll HJ, Jordan K, Huddart R, et al. Testicular seminoma: ESMO Clinical Practice Guidelines for diagnosis, treatment and follow-up. *Ann Oncol* 2010;21 Suppl 5:v140-146. Available at: <http://www.ncbi.nlm.nih.gov/pubmed/20555065>.

83. Flechon A, Bompas E, Biron P, Droz JP. Management of post-chemotherapy residual masses in advanced seminoma. *J Urol* 2002;168:1975-1979. Available at: <http://www.ncbi.nlm.nih.gov/pubmed/12394688>

84. Herr HW, Sheinfeld J, Puc HS, et al. Surgery for a post-chemotherapy residual mass in seminoma. *J Urol* 1997;157:860-862. Available at: <http://www.ncbi.nlm.nih.gov/pubmed/9072586>.

85. de Wit M, Brenner W, Hartmann M, et al. [18F]-FDG-PET in clinical stage I/II non-seminomatous germ cell tumours: results of the German multicentre trial. *Ann Oncol* 2008;19:1619-1623. Available at: <http://www.ncbi.nlm.nih.gov/pubmed/18453520>.

86. Huddart RA, O'Doherty MJ, Padhani A, et al. 18fluorodeoxyglucose positron emission tomography in the prediction of relapse in patients with high-risk, clinical stage I nonseminomatous germ cell tumors: preliminary report of MRC Trial TE22--the NCRI Testis Tumour Clinical Study Group. *J Clin Oncol* 2007;25:3090-3095. Available at: <http://www.ncbi.nlm.nih.gov/pubmed/17634488>.

87. Sheinfeld J, Herr HW. Role of surgery in management of germ cell tumor. *Semin Oncol* 1998;25:203-209. Available at: <http://www.ncbi.nlm.nih.gov/pubmed/9562453>.

88. Colls BM, Harvey VJ, Skelton L, et al. Late results of surveillance of clinical stage I nonseminoma germ cell testicular tumours: 17 years' experience in a national study in New Zealand. *BJU Int* 1999;83:76-82. Available at: <http://www.ncbi.nlm.nih.gov/pubmed/10233456>.

89. Read G, Stenning SP, Cullen MH, et al. Medical Research Council prospective study of surveillance for stage I testicular teratoma. Medical Research Council Testicular Tumors Working Party. *J Clin Oncol* 1992;10:1762-1768. Available at: <http://www.ncbi.nlm.nih.gov/pubmed/1403057>.
90. Sturgeon JF, Moore MJ, Kakiashvili DM, et al. Non-risk-adapted surveillance in clinical stage I nonseminomatous germ cell tumors: the Princess Margaret Hospital's experience. *Eur Urol* 2011;59:556-562. Available at: <http://www.ncbi.nlm.nih.gov/pubmed/21190791>.
91. Zuniga A, Kakiashvili D, Jewett MA. Surveillance in stage I nonseminomatous germ cell tumours of the testis. *BJU Int* 2009;104:1351-1356. Available at: <http://www.ncbi.nlm.nih.gov/pubmed/19840012>.
92. Oliver RT, Ong J, Shamash J, et al. Long-term follow-up of Anglian Germ Cell Cancer Group surveillance versus patients with Stage 1 nonseminoma treated with adjuvant chemotherapy. *Urology* 2004;63:556-561. Available at: <http://www.ncbi.nlm.nih.gov/pubmed/15028457>.
93. de Bruin MJ, Oosterhof GO, Debruyne FM. Nerve-sparing retroperitoneal lymphadenectomy for low stage testicular cancer. *Br J Urol* 1993;71:336-339. Available at: <http://www.ncbi.nlm.nih.gov/pubmed/8386581>.
94. Stephenson AJ, Bosl GJ, Motzer RJ, et al. Retroperitoneal lymph node dissection for nonseminomatous germ cell testicular cancer: impact of patient selection factors on outcome. *J Clin Oncol* 2005;23:2781-2788. Available at: <http://www.ncbi.nlm.nih.gov/pubmed/15837993>.
95. Bohlen D, Borner M, Sonntag RW, et al. Long-term results following adjuvant chemotherapy in patients with clinical stage I testicular nonseminomatous malignant germ cell tumors with high risk factors. *J Urol* 1999;161:1148-1152. Available at: <http://www.ncbi.nlm.nih.gov/pubmed/10081858>.
96. Bohlen D, Burkhard FC, Mills R, et al. Fertility and sexual function following orchiectomy and 2 cycles of chemotherapy for stage I high risk nonseminomatous germ cell cancer. *J Urol* 2001;165:441-444. Available at: <http://www.ncbi.nlm.nih.gov/pubmed/11176393>.
97. Chevreau C, Mazerolles C, Soulie M, et al. Long-term efficacy of two cycles of BEP regimen in high-risk stage I nonseminomatous testicular germ cell tumors with embryonal carcinoma and/or vascular invasion. *Eur Urol* 2004;46:209-214. Available at: <http://www.ncbi.nlm.nih.gov/pubmed/15245815>.
98. Cullen MH, Stenning SP, Parkinson MC, et al. Short-course adjuvant chemotherapy in high-risk stage I nonseminomatous germ cell tumors of the testis: a Medical Research Council report. *J Clin Oncol* 1996;14:1106-1113. Available at: <http://www.ncbi.nlm.nih.gov/pubmed/8648364>.
99. Oliver RT, Raja MA, Ong J, Gallagher CJ. Pilot study to evaluate impact of a policy of adjuvant chemotherapy for high risk stage 1 malignant teratoma on overall relapse rate of stage 1 cancer patients. *J Urol* 1992;148:1453-1455. Available at: <http://www.ncbi.nlm.nih.gov/pubmed/1279211>.
100. Pont J, Albrecht W, Postner G, et al. Adjuvant chemotherapy for high-risk clinical stage I nonseminomatous testicular germ cell cancer: long-term results of a prospective trial. *J Clin Oncol* 1996;14:441-448. Available at: <http://www.ncbi.nlm.nih.gov/pubmed/8636755>.
101. Studer UE, Fey MF, Calderoni A, et al. Adjuvant chemotherapy after orchiectomy in high-risk patients with clinical stage I non-seminomatous testicular cancer. *Eur Urol* 1993;23:444-449. Available at: <http://www.ncbi.nlm.nih.gov/pubmed/7687549>.
102. Sharir S, Foster RS, Donohue JP, Jewett MA. What is the appropriate follow-up after treatment? *Semin Urol Oncol* 1996;14:45-53. Available at: <http://www.ncbi.nlm.nih.gov/pubmed/8833389>.

103. Studer UE, Fey MF, Calderoni A, et al. Adjuvant chemotherapy after orchiectomy in high-risk patients with clinical stage I non-seminomatous testicular cancer. *Eur Urol* 1993;23:444-449. Available at: <http://www.ncbi.nlm.nih.gov/pubmed/7687549>.

104. Bohlen D, Borner M, Sonntag RW, et al. Long-term results following adjuvant chemotherapy in patients with clinical stage I testicular nonseminomatous malignant germ cell tumors with high risk factors. *J Urol* 1999;161:1148-1152. Available at: <http://www.ncbi.nlm.nih.gov/pubmed/10081858>.

105. Pont J, Albrecht W, Postner G, et al. Adjuvant chemotherapy for high-risk clinical stage I nonseminomatous testicular germ cell cancer: long-term results of a prospective trial. *J Clin Oncol* 1996;14:441-448. Available at: <http://www.ncbi.nlm.nih.gov/pubmed/8636755>.

106. Chevreau C, Mazerolles C, Soulie M, et al. Long-term efficacy of two cycles of BEP regimen in high-risk stage I nonseminomatous testicular germ cell tumors with embryonal carcinoma and/or vascular invasion. *Eur Urol* 2004;46:209-214; discussion 214-205. Available at: <http://www.ncbi.nlm.nih.gov/pubmed/15245815>.

107. Meinardi MT, Gietema JA, van der Graaf WT, et al. Cardiovascular morbidity in long-term survivors of metastatic testicular cancer. *J Clin Oncol* 2000;18:1725-1732. Available at: <http://www.ncbi.nlm.nih.gov/pubmed/10764433>.

108. Berger CC, Bokemeyer C, Schneider M, et al. Secondary Raynaud's phenomenon and other late vascular complications following chemotherapy for testicular cancer. *Eur J Cancer* 1995;31A:2229-2238. Available at: <http://www.ncbi.nlm.nih.gov/pubmed/8652248>.

109. Strumberg D, Brugge S, Korn MW, et al. Evaluation of long-term toxicity in patients after cisplatin-based chemotherapy for non-seminomatous testicular cancer. *Ann Oncol* 2002;13:229-236. Available at: <http://www.ncbi.nlm.nih.gov/pubmed/11885999>.

110. Bokemeyer C, Berger CC, Kuczyk MA, Schmoll HJ. Evaluation of long-term toxicity after chemotherapy for testicular cancer. *J Clin Oncol* 1996;14:2923-2932. Available at: <http://www.ncbi.nlm.nih.gov/pubmed/8918489>.

111. Bajorin DF, Motzer RJ, Rodriguez E, et al. Acute nonlymphocytic leukemia in germ cell tumor patients treated with etoposide-containing chemotherapy. *J Natl Cancer Inst* 1993;85:60-62. Available at: <http://www.ncbi.nlm.nih.gov/pubmed/7677936>.

112. Albers P, Siener R, Krege S, et al. Randomized phase III trial comparing retroperitoneal lymph node dissection with one course of bleomycin and etoposide plus cisplatin chemotherapy in the adjuvant treatment of clinical stage I Nonseminomatous testicular germ cell tumors: AUO trial AH 01/94 by the German Testicular Cancer Study Group. *J Clin Oncol* 2008;26:2966-2972. Available at: <http://www.ncbi.nlm.nih.gov/pubmed/18458040>.

113. Culine S, Theodore C, Terrier-Lacombe MJ, Droz JP. Primary chemotherapy in patients with nonseminomatous germ cell tumors of the testis and biological disease only after orchiectomy. *J Urol* 1996;155:1296-1298. Available at: <http://www.ncbi.nlm.nih.gov/pubmed/8632558>.

114. Davis BE, Herr HW, Fair WR, Bosl GJ. The management of patients with nonseminomatous germ cell tumors of the testis with serologic disease only after orchiectomy. *J Urol* 1994;152:111-113; discussion 114. Available at: <http://www.ncbi.nlm.nih.gov/pubmed/7515445>.

115. Stephenson AJ, Bosl GJ, Motzer RJ, et al. Nonrandomized comparison of primary chemotherapy and retroperitoneal lymph node dissection for clinical stage IIA and IIB nonseminomatous germ cell testicular cancer. *J Clin Oncol* 2007;25:5597-5602. Available at: <http://www.ncbi.nlm.nih.gov/pubmed/18065732>.

116. Weissbach L, Bussar-Maatz R, Flechtner H, et al. RPLND or primary chemotherapy in clinical stage IIA/B nonseminomatous germ

cell tumors? Results of a prospective multicenter trial including quality of life assessment. *Eur Urol* 2000;37:582-594. Available at: <http://www.ncbi.nlm.nih.gov/pubmed/10765098>.

117. Donohue JP, Thornhill JA, Foster RS, et al. Clinical stage B non-seminomatous germ cell testis cancer: the Indiana University experience (1965-1989) using routine primary retroperitoneal lymph node dissection. *Eur J Cancer* 1995;31A:1599-1604. Available at: <http://www.ncbi.nlm.nih.gov/pubmed/7488408>.

118. Pizzocaro G. Retroperitoneal lymph node dissection in clinical stage IIA and IIB nonseminomatous germ cell tumours of the testis. *Int J Androl* 1987;10:269-275. Available at: <http://www.ncbi.nlm.nih.gov/pubmed/3034796>.

119. Culine S, Theodore C, Court BH, et al. Evaluation of primary standard cisplatin-based chemotherapy for clinical stage II non-seminomatous germ cell tumours of the testis. *Br J Urol* 1997;79:258-262. Available at: <http://www.ncbi.nlm.nih.gov/pubmed/9052479>.

120. Rabbani F, Sheinfeld J, Farivar-Mohseni H, et al. Low-volume nodal metastases detected at retroperitoneal lymphadenectomy for testicular cancer: pattern and prognostic factors for relapse. *J Clin Oncol* 2001;19:2020-2025. Available at: <http://www.ncbi.nlm.nih.gov/pubmed/11283135>.

121. Stephenson AJ, Bosl GJ, Bajorin DF, et al. Retroperitoneal lymph node dissection in patients with low stage testicular cancer with embryonal carcinoma predominance and/or lymphovascular invasion. *J Urol* 2005;174:557-560; discussion 560. Available at: <http://www.ncbi.nlm.nih.gov/pubmed/16006891>.

122. Carver BS, Shayegan B, Eggner S, et al. Incidence of metastatic nonseminomatous germ cell tumor outside the boundaries of a modified postchemotherapy retroperitoneal lymph node dissection. *J Clin Oncol* 2007;25:4365-4369. Available at: <http://www.ncbi.nlm.nih.gov/pubmed/17906201>.

123. Williams SD, Stablein DM, Einhorn LH, et al. Immediate adjuvant chemotherapy versus observation with treatment at relapse in pathological stage II testicular cancer. *N Engl J Med* 1987;317:1433-1438. Available at: <http://www.ncbi.nlm.nih.gov/pubmed/2446132>.

124. Sheinfeld J, Motzer RJ, Rabbani F, et al. Incidence and clinical outcome of patients with teratoma in the retroperitoneum following primary retroperitoneal lymph node dissection for clinical stages I and IIA nonseminomatous germ cell tumors. *J Urol* 2003;170:1159-1162. Available at: <http://www.ncbi.nlm.nih.gov/pubmed/14501715>.

125. Vogelzang NJ, Fraley EE, Lange PH, et al. Stage II nonseminomatous testicular cancer: a 10-year experience. *J Clin Oncol* 1983;1:171-178. Available at: <http://www.ncbi.nlm.nih.gov/pubmed/6668498>.

126. Behnia M, Foster R, Einhorn LH, et al. Adjuvant bleomycin, etoposide and cisplatin in pathological stage II non-seminomatous testicular cancer. the Indiana University experience. *Eur J Cancer* 2000;36:472-475. Available at: <http://www.ncbi.nlm.nih.gov/pubmed/10717522>.

127. Kondagunta GV, Sheinfeld J, Mazumdar M, et al. Relapse-free and overall survival in patients with pathologic stage II nonseminomatous germ cell cancer treated with etoposide and cisplatin adjuvant chemotherapy. *J Clin Oncol* 2004;22:464-467. Available at: <http://www.ncbi.nlm.nih.gov/pubmed/14752068>.

128. Motzer RJ, Sheinfeld J, Mazumdar M, et al. Etoposide and cisplatin adjuvant therapy for patients with pathologic stage II germ cell tumors. *J Clin Oncol* 1995;13:2700-2704. Available at: <http://www.ncbi.nlm.nih.gov/pubmed/7595727>.

129. Donohue JP, Thornhill JA, Foster RS, et al. The role of retroperitoneal lymphadenectomy in clinical stage B testis cancer: the Indiana University experience (1965 to 1989). *J Urol* 1995;153:85-89. Available at: <http://www.ncbi.nlm.nih.gov/pubmed/7966799>.

130. Hartlapp JH, Weissbach L, Bussar-Maatz R. Adjuvant chemotherapy in nonseminomatous testicular tumour stage II. *Int J Androl* 1987;10:277-284. Available at: <http://www.ncbi.nlm.nih.gov/pubmed/2438221>.

131. Horwich A, Norman A, Fisher C, et al. Primary chemotherapy for stage II nonseminomatous germ cell tumors of the testis. *J Urol* 1994;151:72-77. Available at: <http://www.ncbi.nlm.nih.gov/pubmed/8254836>.

132. Logothetis CJ, Swanson DA, Dexeus F, et al. Primary chemotherapy for clinical stage II nonseminomatous germ cell tumors of the testis: a follow-up of 50 patients. *J Clin Oncol* 1987;5:906-911. Available at: <http://www.ncbi.nlm.nih.gov/pubmed/2438389>.

133. Sternberg CN. Role of primary chemotherapy in stage I and low-volume stage II nonseminomatous germ-cell testis tumors. *Urol Clin North Am* 1993;20:93-9109. Available at: <http://www.ncbi.nlm.nih.gov/pubmed/8382000>.

134. Bosl GJ, Geller NL, Bajorin D, et al. A randomized trial of etoposide + cisplatin versus vinblastine + bleomycin + cisplatin + cyclophosphamide + dactinomycin in patients with good-prognosis germ cell tumors. *J Clin Oncol* 1988;6:1231-1238. Available at: <http://www.ncbi.nlm.nih.gov/pubmed/2457657>.

135. Williams SD, Birch R, Einhorn LH, et al. Treatment of disseminated germ-cell tumors with cisplatin, bleomycin, and either vinblastine or etoposide. *N Engl J Med* 1987;316:1435-1440. Available at: <http://www.ncbi.nlm.nih.gov/pubmed/2437455>.

136. Einhorn LH, Williams SD, Loehrer PJ, et al. Evaluation of optimal duration of chemotherapy in favorable-prognosis disseminated germ cell tumors: a Southeastern Cancer Study Group protocol. *J Clin Oncol* 1989;7:387-391. Available at: <http://www.ncbi.nlm.nih.gov/pubmed/2465391>.

137. de Wit R, Stoter G, Kaye SB, et al. Importance of bleomycin in combination chemotherapy for good-prognosis testicular nonseminoma: a randomized study of the European Organization for Research and Treatment of Cancer Genitourinary Tract Cancer Cooperative Group. *J Clin Oncol* 1997;15:1837-1843. Available at: <http://www.ncbi.nlm.nih.gov/pubmed/9164193>.

138. Horwich A, Sleijfer DT, Fossa SD, et al. Randomized trial of bleomycin, etoposide, and cisplatin compared with bleomycin, etoposide, and carboplatin in good-prognosis metastatic nonseminomatous germ cell cancer: a Multiinstitutional Medical Research Council/European Organization for Research and Treatment of Cancer Trial. *J Clin Oncol* 1997;15:1844-1852. Available at: <http://www.ncbi.nlm.nih.gov/pubmed/9164194>.

139. Jones RH, Vasey PA. Part II: testicular cancer--management of advanced disease. *Lancet Oncol* 2003;4:738-747. Available at: <http://www.ncbi.nlm.nih.gov/pubmed/14662430>.

140. de Wit R, Stoter G, Sleijfer DT, et al. Four cycles of BEP vs four cycles of VIP in patients with intermediate-prognosis metastatic testicular non-seminoma: a randomized study of the EORTC Genitourinary Tract Cancer Cooperative Group. *European Organization for Research and Treatment of Cancer. Br J Cancer* 1998;78:828-832. Available at: <http://www.ncbi.nlm.nih.gov/pubmed/9743309>.

141. Frohlich MW, Small EJ. Stage II nonseminomatous testis cancer: the roles of primary and adjuvant chemotherapy. *Urol Clin North Am* 1998;25:451-459. Available at: <http://www.ncbi.nlm.nih.gov/pubmed/9728214>.

142. Nichols CR, Catalano PJ, Crawford ED, et al. Randomized comparison of cisplatin and etoposide and either bleomycin or ifosfamide in treatment of advanced disseminated germ cell tumors: an Eastern Cooperative Oncology Group, Southwest Oncology Group, and Cancer and Leukemia Group B Study. *J Clin Oncol*

1998;16:1287-1293. Available at:

<http://www.ncbi.nlm.nih.gov/pubmed/9552027>.

143. Toner GC, Panicek DM, Heelan RT, et al. Adjunctive surgery after chemotherapy for nonseminomatous germ cell tumors: recommendations for patient selection. *J Clin Oncol* 1990;8:1683-1694. Available at: <http://www.ncbi.nlm.nih.gov/pubmed/2170590>.

144. Kuczyk M, Machtens S, Stief C, Jonas U. Management of the post-chemotherapy residual mass in patients with advanced stage non-seminomatous germ cell tumors (NSGCT). *Int J Cancer* 1999;83:852-855. Available at: <http://www.ncbi.nlm.nih.gov/pubmed/10597210>.

145. Hartmann JT, Schmoll HJ, Kuczyk MA, et al. Postchemotherapy resections of residual masses from metastatic non-seminomatous testicular germ cell tumors. *Ann Oncol* 1997;8:531-538. Available at: <http://www.ncbi.nlm.nih.gov/pubmed/9261521>.

146. Motzer RJ, Geller NL, Tan CC, et al. Salvage chemotherapy for patients with germ cell tumors. The Memorial Sloan-Kettering Cancer Center experience (1979-1989). *Cancer* 1991;67:1305-1310. Available at: <http://www.ncbi.nlm.nih.gov/pubmed/1703917>.

147. Einhorn LH, Williams SD, Chamness A, et al. High-dose chemotherapy and stem-cell rescue for metastatic germ-cell tumors. *N Engl J Med* 2007;357:340-348. Available at: <http://www.ncbi.nlm.nih.gov/pubmed/17652649>.

148. Lorch A, Beyer J, Bascoul-Mollevis C, et al. Prognostic factors in patients with metastatic germ cell tumors who experienced treatment failure with cisplatin-based first-line chemotherapy. *J Clin Oncol* 2010;28:4906-4911. Available at: <http://www.ncbi.nlm.nih.gov/pubmed/20956623>.

149. Loehrer PJ, Sr., Gonin R, Nichols CR, et al. Vinblastine plus ifosfamide plus cisplatin as initial salvage therapy in recurrent germ

cell tumor. *J Clin Oncol* 1998;16:2500-2504. Available at:

<http://www.ncbi.nlm.nih.gov/pubmed/9667270>.

150. Lorch A, Rick O, Wundisch T, et al. High dose chemotherapy as salvage treatment for unresectable late relapse germ cell tumors. *J Urol* 2010;184:168-173. Available at: <http://www.ncbi.nlm.nih.gov/pubmed/20483152>.

151. Lorch A, Neubauer A, Hackenthal M, et al. High-dose chemotherapy (HDCT) as second-salvage treatment in patients with multiple relapsed or refractory germ-cell tumors. *Ann Oncol* 2010;21:820-825. Available at: <http://www.ncbi.nlm.nih.gov/pubmed/19822531>.

152. Albers P, Ganz A, Hannig E, et al. Salvage surgery of chemorefractory germ cell tumors with elevated tumor markers. *J Urol* 2000;164:381-384. Available at: <http://www.ncbi.nlm.nih.gov/pubmed/10893590>.

153. Kisbenedek L, Bodrogi I, Szeldeli P, et al. Results of salvage retroperitoneal lymphadenectomy (RLA) in the treatment of patients with nonseminomatous germ cell tumours remaining marker positive after inductive chemotherapy. *Int Urol Nephrol* 1995;27:325-329. Available at: <http://www.ncbi.nlm.nih.gov/pubmed/7591598>.

154. Motzer RJ, Bosl GJ. High-dose chemotherapy for resistant germ cell tumors: recent advances and future directions. *J Natl Cancer Inst* 1992;84:1703-1709. Available at: <http://www.ncbi.nlm.nih.gov/pubmed/1331482>.

155. Feldman DR, Sheinfeld J, Bajorin DF, et al. TI-CE high-dose chemotherapy for patients with previously treated germ cell tumors: results and prognostic factor analysis. *J Clin Oncol* 2010;28:1706-1713. Available at: <http://www.ncbi.nlm.nih.gov/pubmed/20194867>.

156. Baniel J, Foster RS, Gonin R, et al. Late relapse of testicular cancer. *J Clin Oncol* 1995;13:1170-1176. Available at: <http://www.ncbi.nlm.nih.gov/pubmed/7537800>.

157. George DW, Foster RS, Hromas RA, et al. Update on late relapse of germ cell tumor: a clinical and molecular analysis. *J Clin Oncol* 2003;21:113-122. Available at: <http://www.ncbi.nlm.nih.gov/pubmed/12506179>.

158. Lipphardt ME, Albers P. Late relapse of testicular cancer. *World J Urol* 2004;22:47-54. Available at: <http://www.ncbi.nlm.nih.gov/pubmed/15064970>.

159. Gerl A, Clemm C, Schmeller N, et al. Late relapse of germ cell tumors after cisplatin-based chemotherapy. *Ann Oncol* 1997;8:41-47. Available at: <http://www.ncbi.nlm.nih.gov/pubmed/9093706>.

160. Eastham JA, Wilson TG, Russell C, et al. Surgical resection in patients with nonseminomatous germ cell tumor who fail to normalize serum tumor markers after chemotherapy. *Urology* 1994;43:74-80. Available at: <http://www.ncbi.nlm.nih.gov/pubmed/7506856>.

161. Wood DP, Jr., Herr HW, Motzer RJ, et al. Surgical resection of solitary metastases after chemotherapy in patients with nonseminomatous germ cell tumors and elevated serum tumor markers. *Cancer* 1992;70:2354-2357. Available at: <http://www.ncbi.nlm.nih.gov/pubmed/1382832>.

162. De Giorgi U, Rosti G, Aieta M, et al. Phase II study of oxaliplatin and gemcitabine salvage chemotherapy in patients with cisplatin-refractory nonseminomatous germ cell tumor. *Eur Urol* 2006;50:1032-1038; discussion 1038-1039. Available at: <http://www.ncbi.nlm.nih.gov/pubmed/16757095>.

163. Kollmannsberger C, Beyer J, Liersch R, et al. Combination chemotherapy with gemcitabine plus oxaliplatin in patients with intensively pretreated or refractory germ cell cancer: a study of the German Testicular Cancer Study Group. *J Clin Oncol* 2004;22:108-114. Available at: <http://www.ncbi.nlm.nih.gov/pubmed/14701772>.

164. Pectasides D, Pectasides M, Farmakis D, et al. Gemcitabine and oxaliplatin (GEMOX) in patients with cisplatin-refractory germ cell

tumors: a phase II study. *Ann Oncol* 2004;15:493-497. Available at: <http://www.ncbi.nlm.nih.gov/pubmed/14998855>.

165. Bokemeyer C, Oechsle K, Honecker F, et al. Combination chemotherapy with gemcitabine, oxaliplatin, and paclitaxel in patients with cisplatin-refractory or multiply relapsed germ-cell tumors: a study of the German Testicular Cancer Study Group. *Ann Oncol* 2008;19:448-453. Available at: <http://www.ncbi.nlm.nih.gov/pubmed/18006893>.

166. Einhorn LH, Brames MJ, Juliar B, Williams SD. Phase II study of paclitaxel plus gemcitabine salvage chemotherapy for germ cell tumors after progression following high-dose chemotherapy with tandem transplant. *J Clin Oncol* 2007;25:513-516. Available at: <http://www.ncbi.nlm.nih.gov/pubmed/17290059>.

167. Mulherin BP, Brames MJ, Einhorn LH. Long-term survival with paclitaxel and gemcitabine for germ cell tumors after progression following high-dose chemotherapy with tandem transplants [abstract]. *J Clin Oncol* 2011;29:Abstract 4562. Available at: http://meeting.ascopubs.org/cgi/content/abstract/29/15_suppl/4562.

168. Miller JC, Einhorn LH. Phase II study of daily oral etoposide in refractory germ cell tumors. *Semin Oncol* 1990;17:36-39. Available at: <http://www.ncbi.nlm.nih.gov/pubmed/2154858>.

169. Fossa SD, Bokemeyer C, Gerl A, et al. Treatment outcome of patients with brain metastases from malignant germ cell tumors. *Cancer* 1999;85:988-997. Available at: <http://www.ncbi.nlm.nih.gov/pubmed/10091779>.

170. Hartmann J, Bamberg M, Albers P, et al. Multidisciplinary treatment and prognosis of patients with central nervous metastases (CNS) from testicular germ cell tumour (GCT) origin [abstract] *Proc Ann Soc Clin Oncol* 2003;22:400:Abstract 1607.

171. Bokemeyer C, Nowak P, Haupt A, et al. Treatment of brain metastases in patients with testicular cancer. *J Clin Oncol*



National
Comprehensive
Cancer
Network®

NCCN Guidelines Version 2.2015

Testicular Cancer

[NCCN Guidelines Index](#)
[Testicular Cancer TOC](#)
[Discussion](#)

1997;15:1449-1454. Available at:
<http://www.ncbi.nlm.nih.gov/pubmed/9193339>.